

COMPARISON BETWEEN POVIDONE IODINE 10% AND ALOE VERA GEL ON BURN WOUND HEALING IN WISTAR RATS (RATTUS NORVEGICUS)

Jesselyn Felicia¹, Dewi Fibrini², Anita Rosari Dalimunthe³

^{1,2,3} Faculty of Medicine, Dentistry and Health Sciences, Universitas Prima Indonesia, Indonesia

Email: jlynfelicia@gmail.com, dewifibrini@gmail.com, dalimuntheanita@yahoo.com

ABSTRACT

Aloe vera has long been known for its diverse properties, including wound healing. Compounds such as saponins, tannins, and polyphenols contained in aloe vera provide anti-inflammatory, antibacterial, and accelerate tissue regeneration. This study aims to compare the effectiveness between Povidone Iodine 10% and Aloe Vera Gel on burn wound healing in Wistar Rats (Rattus norvegicus). The study used an experimental design with post-test only control group design. A total of 33 rats were divided into three groups: control group without treatment, Povidone Iodine 10% group, and Aloe Vera Gel group. Observations were made on days 0, 7, and 14 with parameters of wound diameter, percentage of wound reduction, and histopathological analysis to assess the amount of blood vessel formation, fibroblasts, macrophages, and epidermal thickness. The results showed that the administration of Aloe Vera Gel is effective in healing burn wounds, especially in the inflammatory and proliferation phases.

KEYWORDS Burns, Povidone Iodine 10%, Aloe Vera Gel, Wistar Rats, Wound Healing



This work is licensed under a Creative Commons Attribution-ShareAlike 4.0 International

INTRODUCTION

Burns are one of the most common forms of injury. Burns are characterized by tissue damage or loss resulting from contact between the skin and heat, radiation, electricity, and chemicals.

Damage to skin tissue increases the risk of exposure to bacteria and other pathogens due to the loss of the protective layer. Burns are classified into 3 degrees based on the extent and depth of tissue damage. (Alepandi et al., 2022; Tammam et al., 2023).. First-degree burns affect the epidermis and are characterized by redness, slight edema, and pain. Second-degree burns affect the epidermis and part of the dermis and are characterized by the formation of ulcers, edema, and severe pain.

How to cite:

Jesselyn Felicia, et al. (2024). A Comparison Between The Administration Of Povidone Iodine 10% And Aloe Vera Gel On The Healing Of Wistar Rat Burns (Rattus Norvegicus). *Journal Eduvest*. 4(12), 11255-11273

E-ISSN:

2775-3727

Third-degree burns affect the entire epidermis, dermis, hypodermis, and reach the muscles and nerves. (Uswatun Hasanah et al., 2023)..

According to the World Health Organization (WHO), the worldwide death rate from burns was estimated at 265,000 in 2015. WHO data in 2016 recorded the highest prevalence of burns in the Southeast Asian Region with death rates per 100,000 people per year in the countries of Indonesia (172.7/100,000), Cambodia (165.4/100,000), and Laos (151.3/100,000). The incidence of burns in Indonesia is very high, with more than 250 people dying each year from burns (Adimaharani, N.M.L., 2019).

According to data from the 2013 Basic Health Research (Riskesdas), there was a 35% increase in the incidence of burns in Indonesia from 2014 to 2018. In 2018, there were 1,701 cases (20.19%), in 2017 there were 1,570 cases (18.64%), in 2016 there were 1,432 cases (17.03%), in 2015 there were 1,387 cases (16.46%), and in 2014 there were 1,209 cases (14.35%). The prevalence of burns in Indonesia reached 2.2%, occurring in several provinces such as Nangroe Aceh Darusalam (5.2%), Riau Islands (3.8%), and the highest in Bali Province with 6.8%. According to Riskesdas data for Medan City, from January to December 2016, there were a total of 89 cases of burned individuals in North Sumatra. The region with the highest prevalence of burns is in Bali Province (Adimaharani, N.M.L., 2019; Weny Andriany Sinaga, 2022).

Currently, people still use traditional medicine and herbal ingredients as an alternative treatment, therefore complementary therapy is needed in healing burn wounds and to support the role of topical antimicrobials. Aloe vera or aloe vera is one of the alternative medicines that can be used as a burn medicine because the content in it can act as an antibacterial. Aloe vera is a plant native to the semi-tropical region and is considered one of the herbal plants with diverse benefits. Characteristics of aloe vera include thick, tapered leaves, with short stalks from the ground. Although not part of the cactus family, aloe vera belongs to the *lily* tree family, known as *Aloe barbadensis miller* (Alepani et al., 2022).

Previous studies have shown that aloe vera is effective in wound healing in various animal models. Aloe vera's antimicrobial, antioxidant, and anti-inflammatory properties make an important contribution to the treatment of wounds, minor burns, and skin irritations. Aloe vera also contains bradykinin and thromboxane substances that have been shown to be effective in reducing pain and accelerating the wound healing process by facilitating the removal of dead skin cells. (Hai et al., 2019).

Until recently, the standard treatment for burns involved the use of antiseptics, antimicrobials and anti-inflammatories. *Povidone iodine* is one of the most commonly used antiseptics. *Povidone iodine* is a local anti-bacterial compound that is efficient in eradicating microorganisms such as bacteria, fungi, protozoa, viruses and spores, and is commonly used as a skin antiseptic. (Prasetya & Suhaymi, 2020; Research et al., 2023)..

In preclinical research, it is necessary to conduct a series of trials using animal models before the experiment is implemented in humans. Rodents (rodentia order) such as white rats (*Rattus norvegicus*), mice (*Mus musculus*) and rabbits have physiological functions similar to humans so they are often used as experimental

models. Most biomedical research uses experimental animals such as Wistar rats, mice and rabbits.(Alepandi et al., 2022).

This study aims to compare the epithelialization process between Povidone Iodine 10% and Aloe Vera gel in healing burn wounds in Wistar rats. The formulation of the problem proposed is how the comparison of the epithelialization process of the two materials in healing burn wounds. The objectives of this study include the general objective, which is to compare the effectiveness of the two materials in healing burn wounds, as well as specific objectives to compare the effectiveness on days 0, 7, and 14, and to analyze differences in biological responses in burn wounds treated with each material. The benefits of this study include theoretical benefits that support herbal treatment with natural ingredients and provide insight for further research, as well as practical benefits as a cheap and affordable alternative treatment.

RESEARCH METHOD

This study used a true experimental design with post-test only control group design. There was one control group that was not treated, and two treatment groups, namely the group of rats treated with Povidone Iodine 10% and the group of rats treated with Aloe Vera gel. The study aimed to evaluate the comparison of the burn wound healing process in each treatment group.

This research will be conducted at the University of North Sumatra Laboratory from April to June 2024. The location was chosen to support the implementation of experiments with adequate facilities. The research time was chosen to provide enough time for observation of the wound healing process in Wistar rats.

The population of this study consisted of male Wistar rats (*Rattus norvegicus*) with body weight of 150-200 grams and age of 2-3 months, which were divided into three groups. Based on calculations using the Federer formula, the number of samples required was 9 rats for each group, with a total of 27 rats used in this study.

RESULT AND DISCUSSION

Burn Diameter Data

The effect of aloe vera gel on the diameter of wistar rat burn wounds was studied in this study. Diameter data will be presented as *mean* ± standard deviation (*mean* ± *SD*).

Table 4.1 Comparison of mean burn diameter (mm)

Day	Group	Mean ± standard deviation
0	NaCl	22,46 ±1,40
	<i>Povidone Iodine 10%</i>	23,34±1,43
	Aloe Vera Gel	23,01±0,77
7	NaCl	19,52±1,83
	<i>Povidone Iodine 10%</i>	17,89±1,24
	Aloe Vera Gel	17,60±1,63
14	NaCl	13,23±3,21

<i>Povidone Iodine 10%</i>	9,52±3,53
Aloe Vera Gel	11,30±2,40

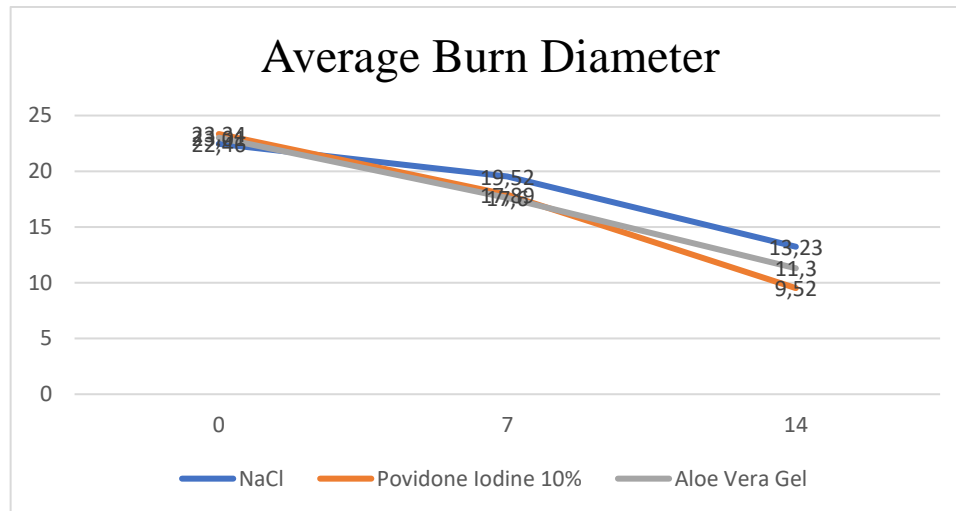


Figure 1. Comparison of mean burn diameter

According to table 1 and graph 1, it can be indicated that the average diameter in the NaCl, *povidone iodine 10%* and aloe vera gel groups experienced a gradual decrease in wound diameter until day 14. In the group treated with *povidone iodine 10%*, the wound diameter decreased from 23.34±1.43 on day 7 to 9.52±3.53 on day 14. This case shows that the group treated with *povidone iodine 10%* had the most significant decrease in wound diameter at the end of the study compared to the other groups. Before performing statistical analysis to compare the diameter between groups, data normality testing will be carried out using the *Shapiro-Wilk* test due to the number of samples less than 50.

Table 2. Normality test of burn diameter

Day	Group	<i>P-value</i>
0	NaCl	0,799
	<i>Povidone Iodine 10%</i>	0,772
	Aloe Vera Gel	0,469
7	NaCl	0,269
	<i>Povidone Iodine 10%</i>	0,834
	Aloe Vera Gel	0,710
14	NaCl	0,887
	<i>Povidone Iodine 10%</i>	0,404
	Aloe Vera Gel	0,280

Table 2 displays the results of the normality test for the diameter of burn wounds in several treatment groups over three time points. Table 2 shows that all data are normally distributed (*p value* > 0.05) so it will be continued with the *Levene* test to test the homogeneity of the data (*p value* > 0.05). After the data is normally distributed and homogeneous, the data will be analyzed using *One Way ANOVA*.

A Comparison Between The Administration Of Povidone Iodine 10% And Aloe Vera Gel On The Healing Of Wistar Rat Burns (*Rattus Norvegicus*)

Table 3. *Levene's test of burn diameter*

<i>Levene's Test</i>	
Day	<i>P-value</i>
0	0,283
7	0,225
14	0,328

Table 3 shows the results of *Levene's test* for burn diameter fulfill the assumption of homogeneity of variance. This data meets the requirements for statistical analysis which assumes equal variance (p value > 0.05).

Table 4. *ANOVA test of burn wound diameter*

ANOVA	
Day	<i>P-value</i>
0	0,329
7	0,036
14	0,057

Table 4 on day 0 and day 14 shows no significant difference between groups (p value > 0.05). However, on day 7 (p value < 0.05) there was a significant difference between groups. *Post Hoc* test with *Tukey HSD* test was conducted to compare the difference in burn diameter between groups.

Table 5. *Post Hoc test of burn wound diameter*

Day	Group	Comparator	<i>P-value</i>
0	NaCl	<i>Povidone Iodine 10%</i>	0,305
	NaCl	Aloe Vera Gel	0,614
	Aloe Vera Gel	<i>Povidone Iodine 10%</i>	0,843
7	NaCl	<i>Povidone Iodine 10%</i>	0,094
	NaCl	Aloe Vera Gel	0,043*
	Aloe Vera Gel	<i>Povidone Iodine 10%</i>	0,923
14	NaCl	<i>Povidone Iodine 10%</i>	0,045*
	NaCl	Aloe Vera Gel	0,393
	Aloe Vera Gel	<i>Povidone Iodine 10%</i>	0,455

Notes (*): P value < 0.05

Post Hoc test results in table 5 can be concluded that on day 7, significant differences (p value < 0.05) were found between the NaCl and aloe vera gel groups. Significant differences were also found between the NaCl and *povidone iodine 10%* groups on day 14.

Data on Percent Reduction of Burn Diameter

The effect of aloe vera gel on the diameter of the burn wound can also be expressed in the form of a percent reduction presented in table 4.6 below.

Table 6. Average percent reduction in burn wound diameter

Day	Group	Average Percent Reduction in Burn Diameter
7	NaCl	13,61%
	<i>Povidone Iodine 10%</i>	20,63%
	Aloe Vera Gel	23,46%
14	NaCl	40,94%
	<i>Povidone Iodine 10%</i>	59,29%
	Aloe Vera Gel	50,96%

Table 6 shows that on day 7, aloe vera gel had the highest diameter reduction among the three groups (23.46%), followed by *povidone iodine* 10% and NaCl groups. However, on day 14, the *povidone iodine* 10% group showed the greatest decrease (59.29%), followed by the aloe vera gel and NaCl groups. Data normality testing was carried out using the *Shapiro-Wilk test*, if the data was normal (p value > 0.05) then continued with the homogeneity test with the *Levene test*. After the data is normally distributed and homogeneous, it will continue with the *One Way ANOVA test*.

Table 7. Normality test of percent reduction in burn diameter

Day	Group	<i>P-value</i>
7	NaCl	0,964
	<i>Povidone Iodine 10%</i>	0,111
	Aloe Vera Gel	0,108
14	NaCl	0,671
	<i>Povidone Iodine 10%</i>	0,339
	Aloe Vera Gel	0,240

Table 8. *Levene test* of percent reduction in burn diameter

<i>Levene's Test</i>	
Day	<i>P-value</i>
7	0,867
14	0,346

Based on the results of the normality test in table 7 and the *Levene test* in table 8, the results show that the data is normally distributed and the variance between groups is the same or homogeneous on day 7 and day 14. The data test results fulfill the assumptions of normal distribution and homogeneity of variance.

Table 9. *ANOVA test* of percent reduction in burn wound diameter

ANOVA	
Day	<i>P-value</i>
7	0,024
14	0,023

The ANOVA table (Table 9) shows that on day 7 and day 14 there was a significant difference between the study groups (p value <0.05) and to compare the difference in percent reduction in burn wound diameter between groups, a *Post Hoc* test was conducted with the *Tukey HSD test*.

Table 10. *Post Hoc* test of percent reduction in burn wound diameter

Day	Group	Comparator	<i>P</i> -value
7	NaCl	<i>Povidone Iodine 10%</i>	0,123
	NaCl	Aloe Vera Gel	0,022*
	Aloe Vera Gel	<i>Povidone Iodine 10%</i>	0,691
14	NaCl	<i>Povidone Iodine 10%</i>	0,017*
	NaCl	Aloe Vera Gel	0,254
	Aloe Vera Gel	<i>Povidone Iodine 10%</i>	0,380

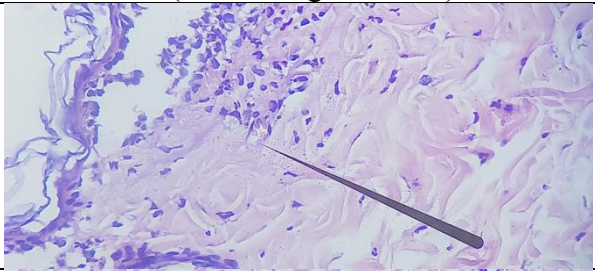
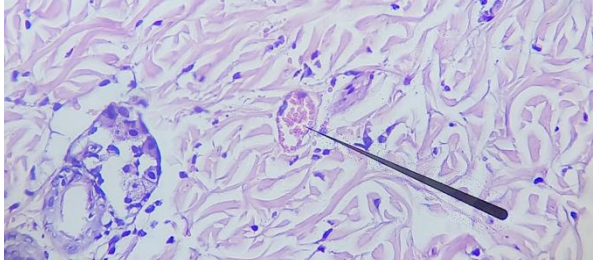
Notes (*): P value <0.05

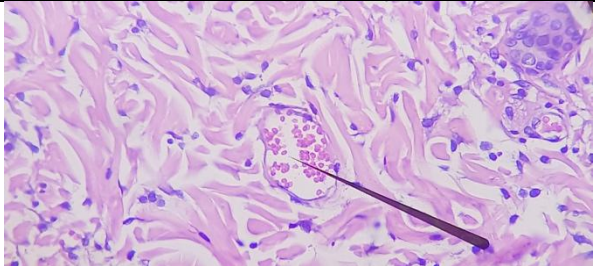
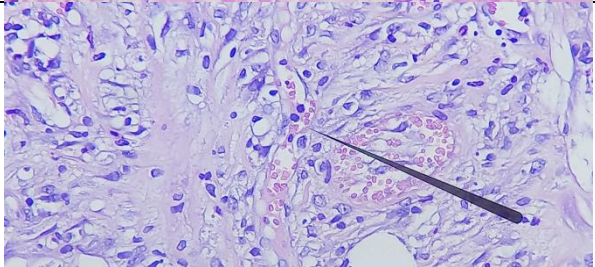
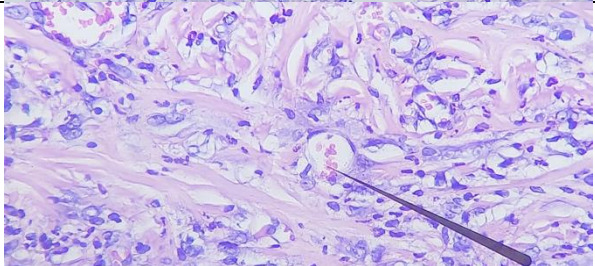
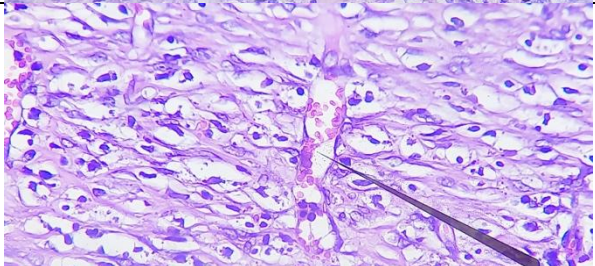
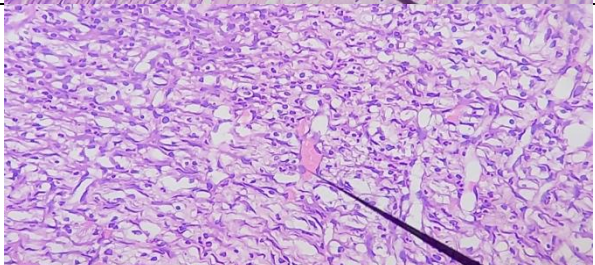
In table 10 *Post Hoc* test, there is a significant difference in percent diameter reduction (p value <0.05) between the NaCl group and aloe vera gel on day 7. On day 14, there was also a significant difference between the NaCl group and *povidone iodine 10%*.

Burn Histopathology

The results of histopathological analysis were assessed with respect to the number of blood vessels, fibroblasts, macrophages and epithelial thickness. The examination was performed using a Zeiss Primo Star microscope (Zeiss, Germany) with 10x ocular magnification and 40x objective lens magnification.

Table 11. Blood vessel histopathology

HISTOPATHOLOGY OF BLOOD VESSELS (10x40 magnification)		
0	NaCl	
	<i>Povidone Iodine 10%</i>	

	Aloe Vera Gel	
7	NaCl	
	<i>Povidone Iodine 10%</i>	
	Aloe Vera Gel	
	14	NaCl
	<i>Povidone Iodine 10%</i>	

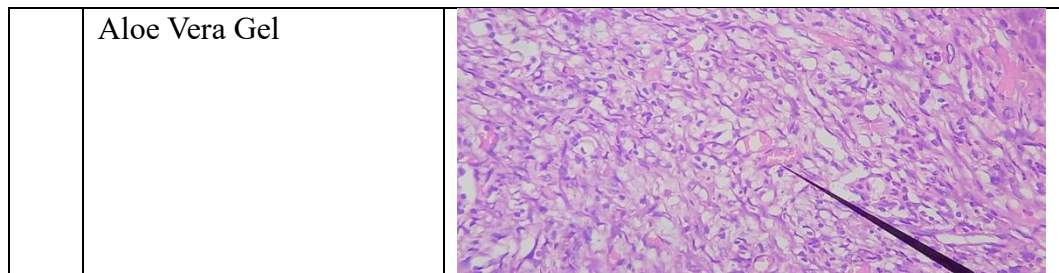


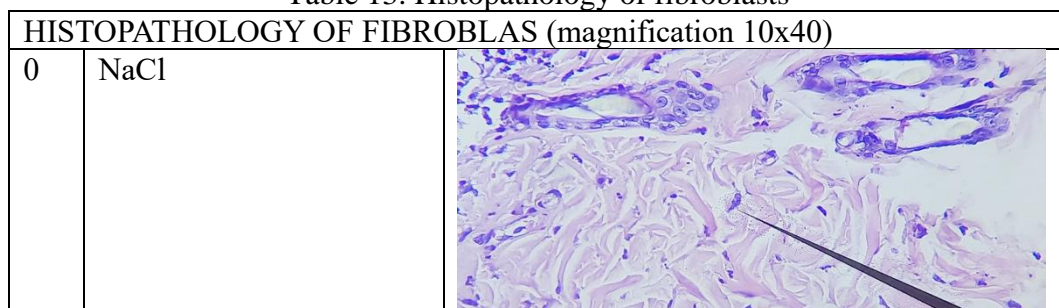
Table 11 shows the results of blood vessel histopathology in the three treatment groups with 10x40 magnification.

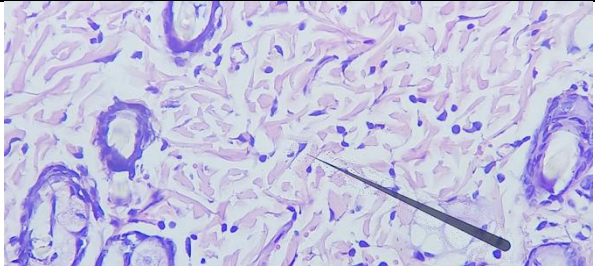
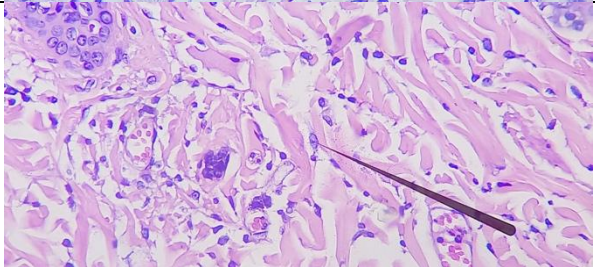
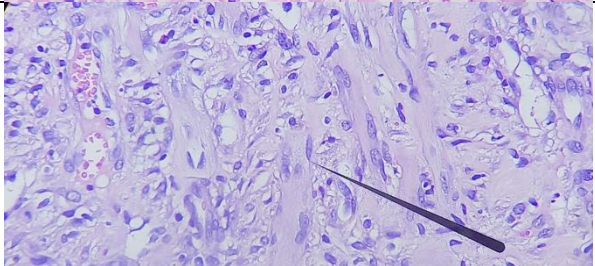
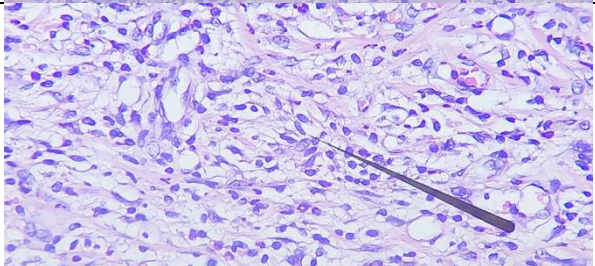
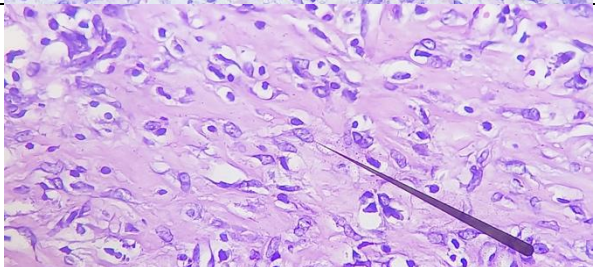
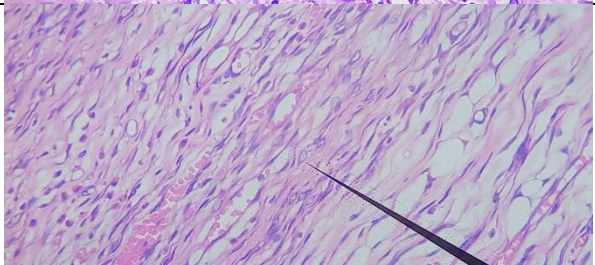
Table 12. Comparison of the average number of blood vessels in each group

Day	Group	Blood Vessels in 3 Fields of View (10 x10)			Average Number
		1	2	3	
0	NaCl	1	2	0	1
	<i>Povidone Iodine 10%</i>	2	3	4	3
	Aloe Vera Gel	1	5	3	3
7	NaCl	10	9	12	10
	<i>Povidone Iodine 10%</i>	5	6	7	6
	Aloe Vera Gel	6	7	5	6
14	NaCl	8	7	13	9
	<i>Povidone Iodine 10%</i>	19	17	18	18
	Aloe Vera Gel	22	12	9	14

Table 12 above states the number of blood vessels in 3 fields of view and the average number of blood vessels. All groups experienced an increase in blood vessels over time. The *povidone iodine 10%* and aloe vera gel groups had more blood vessels than the NaCl group.

Table 13. Histopathology of fibroblasts



	<i>Povidone Iodine 10%</i>	
	Aloe Vera Gel	
7	NaCl	
	<i>Povidone Iodine 10%</i>	
	Aloe Vera Gel	
14	NaCl	

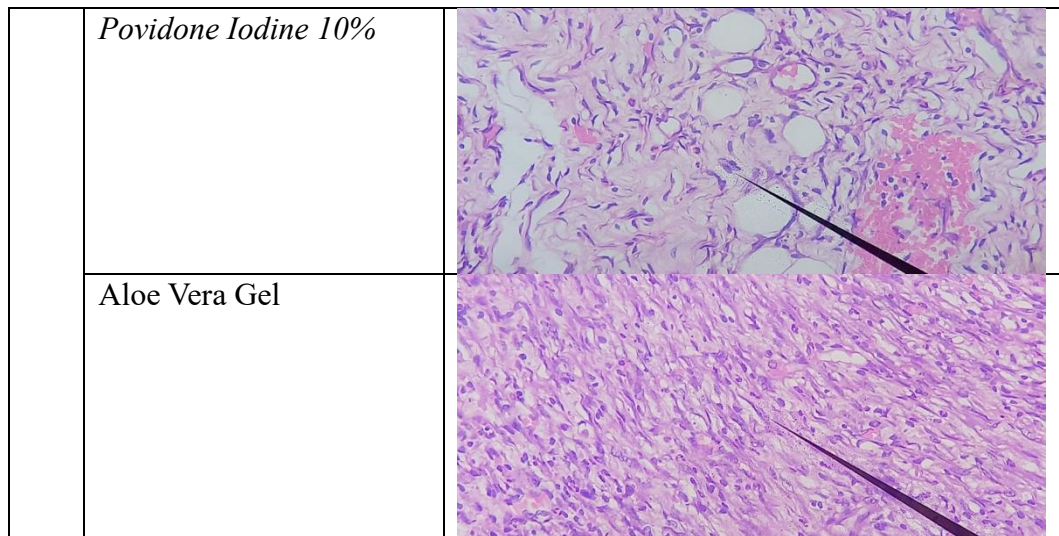


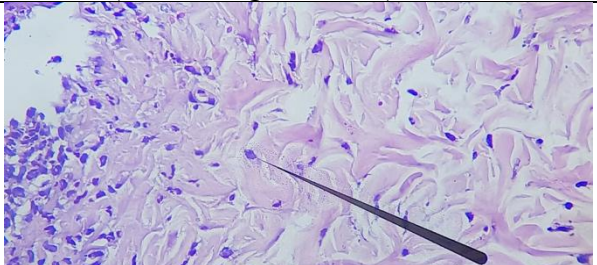
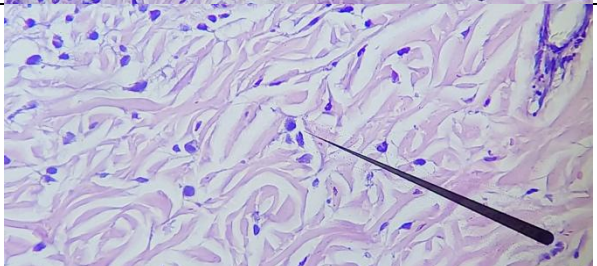
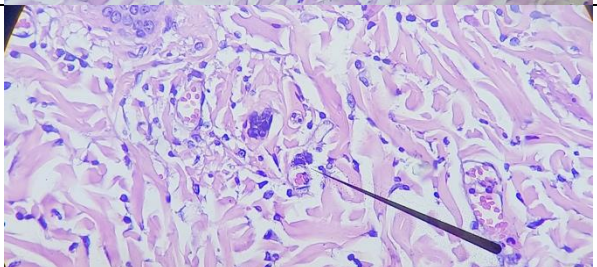
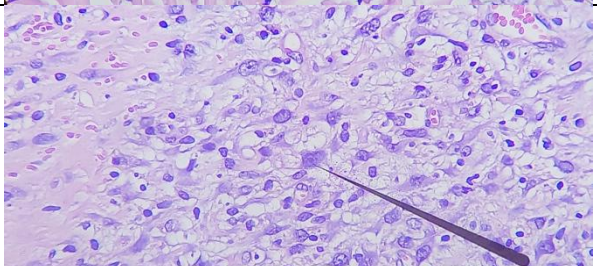
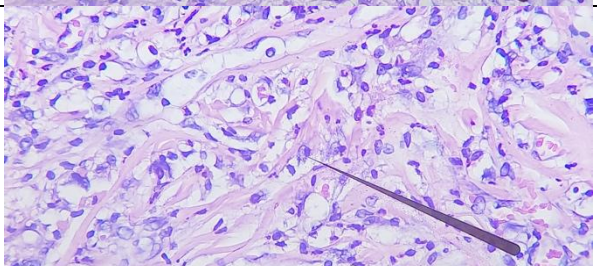
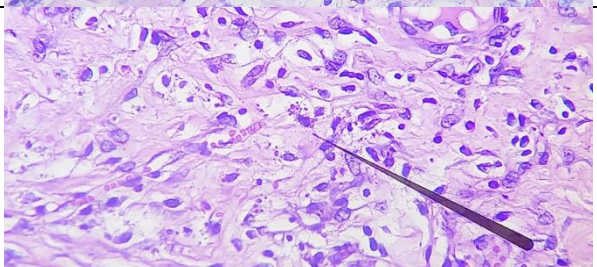
Table 13 is an image of fibroblast histopathology on days 0, 7 and 14 in the NaCl, *povidone iodine 10%* and aloe vera gel groups.

Table 14. Average number of fibroblasts in NaCl, *povidone iodine 10%* and aloe vera gel groups

Day	Group	Fibroblast Count in 3 Fields of View (10 x10)			Average Number
		1	2	3	
0	NaCl	8	12	6	9
	<i>Povidone Iodine 10%</i>	14	17	7	13
	Aloe Vera Gel	6	18	12	12
7	NaCl	102	93	86	94
	<i>Povidone Iodine 10%</i>	129	141	110	127
	Aloe Vera Gel	89	104	76	90
14	NaCl	25	20	35	27
	<i>Povidone Iodine 10%</i>	73	56	41	57
	Aloe Vera Gel	61	48	34	48

Table 14 states the number of fibroblasts in 3 fields of view and the average number of fibroblasts. All groups experienced the most fibroblast growth on day 7 with the highest number of fibroblasts in the *povidone iodine 10%* group. On day 14, *povidone iodine 10%* showed the highest fibroblast activity. Aloe vera gel showed high fibroblast activity, but slightly lower than *povidone iodine 10%*.

Table 15. Macrophage histopathology

MACROPHAGES HISTOPATHOLOGY (10x40 magnification)		
0	NaCl	
	<i>Povidone Iodine 10%</i>	
	Aloe Vera Gel	
7	NaCl	
	<i>Povidone Iodine 10%</i>	
	Aloe Vera Gel	

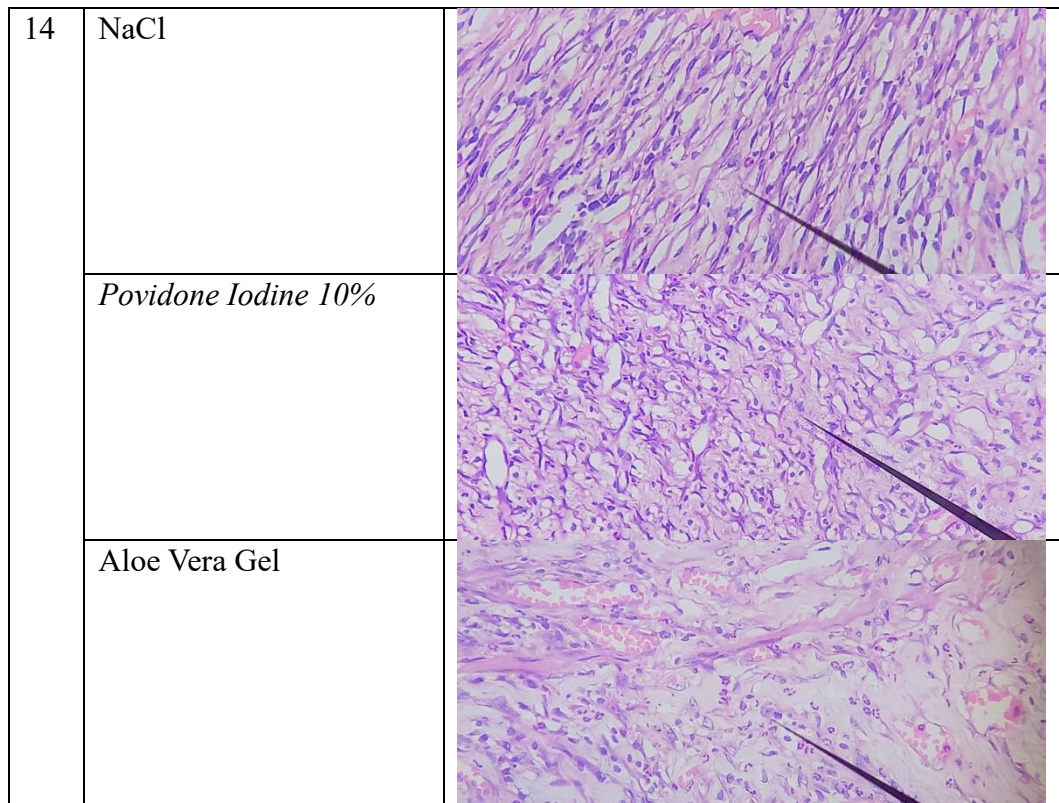


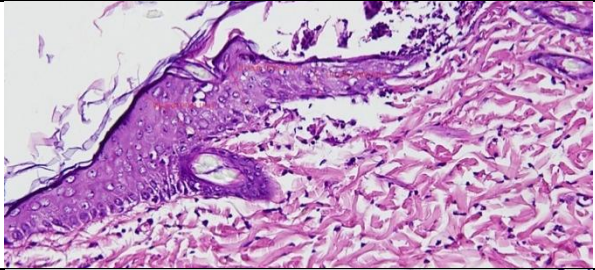
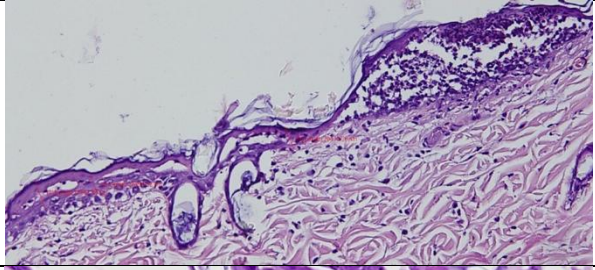
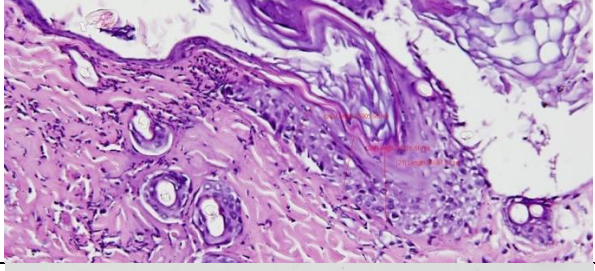
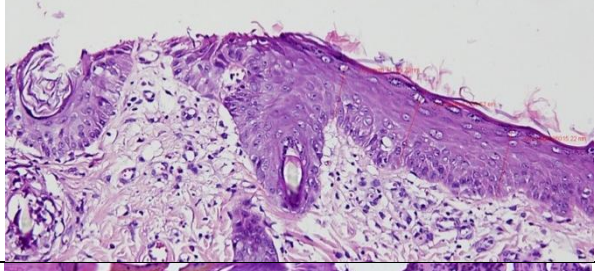
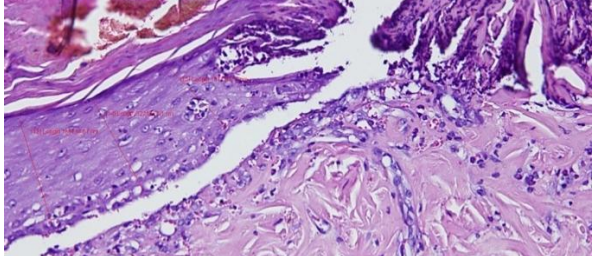
Table 15 is an image of macrophage histopathology on days 0, 7 and 14 in the NaCl, *povidone iodine 10%* and aloe vera gel groups.

Table 16. Average number of macrophages in each group

Day	Group	Number of Macrophages in 3 Fields of View (10 x10)			Average Number
		1	2	3	
0	NaCl	5	4	8	6
	<i>Povidone Iodine 10%</i>	4	3	6	4
	Aloe Vera Gel	0	3	6	3
7	NaCl	3	2	11	5
	<i>Povidone Iodine 10%</i>	9	6	5	7
	Aloe Vera Gel	9	14	12	11
14	NaCl	8	2	5	5
	<i>Povidone Iodine 10%</i>	12	9	6	9
	Aloe Vera Gel	3	10	8	7

Table 16 above states the number of macrophages in 3 fields of view and the average number of macrophages. Based on table 4.16, it can be seen that all groups experienced an increase in macrophages. NaCl group is relatively stable, *10% povidone iodine* group macrophages tend to increase but less than the increase in the number of macrophages in the aloe vera gel group.

Table 17 Histopathology Epidermis

HISTOPATHOLOGY OF EPIDERMIS (magnification 10x200)		
0	NaCl	
	<i>Povidone Iodine 10%</i>	
	Aloe Vera Gel	
7	NaCl	
	<i>Povidone Iodine 10%</i>	

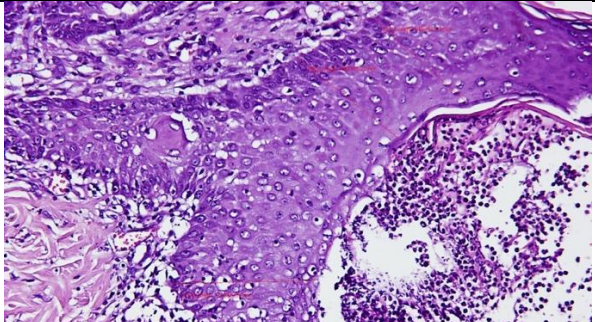
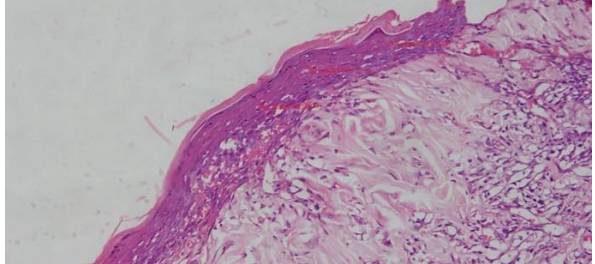
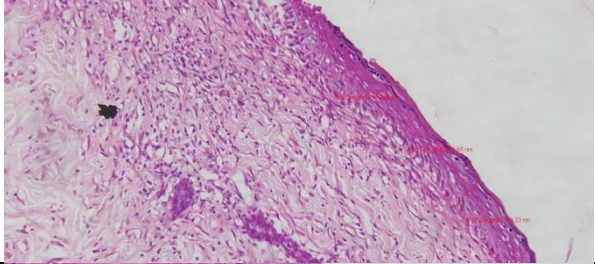
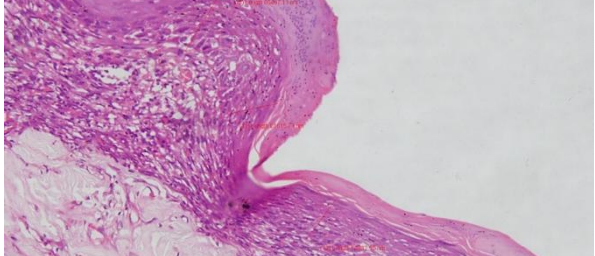
	Aloe Vera Gel	
14	NaCl	
	<i>Povidone Iodine 10%</i>	
	Aloe Vera Gel	

Table 17 is an image of epidermal histopathology on days 0, 7 and 14 in the NaCl, *povidone iodine 10%* and aloe vera gel groups. These results are consistent with other histopathology data.

Table 18. Epidermal thickness measurement (μm)

Day	Group	Epidermal Thickness (in μm) Magnification 10x200			
		1	2	3	Average
0	NaCl	40386,63	75635,22	94164,112	70061,99
	<i>Povidone Iodine 10%</i>	37567,86	27453,32	29414,255	31478,48
	Aloe Vera Gel	55905,98	86697,87	68776,659	70460,17
7	NaCl	71709,2	92389,52	86015,217	83371,31
	<i>Povidone Iodine 10%</i>	133734,7	122142,6	101120,58	118999,28
	Aloe Vera Gel	149854,1	158048,2	173855,69	160586,00

14	NaCl	42249,17	54703,52	67343,00	54765,23
	<i>Povidone Iodine 10%</i>	59509,09	40465,65	45140,226	48371,65
	Aloe Vera Gel	85497,11	61615,71	54832,545	67315,12

Table 18 is the result of measuring the thickness of the epidermis in 10x200 magnification on days 0, 7 and 14 in the NaCl, *povidone iodine 10%* and aloe vera gel groups. In the initial condition, the thickness of the epidermis in the three groups was not too different with *povidone iodine 10%* having the thinnest epidermal thickness. On day-7, epidermal thickness increased in all groups with aloe vera gel showing the greatest increase in thickness (160586.00 μm), followed by *povidone iodine 10%* and NaCl. On day-14, epidermal thickness decreased in all groups compared to day-7. However, aloe vera gel still maintained the highest thickness.

Discussion

Based on table 1, the average diameter of burn wounds, all groups experienced a reduction in diameter. The decrease in diameter can be seen directly from the graph of the average burn diameter. The *povidone iodine 10%* group experienced the largest average decrease (13.82 ± 2.1 mm) followed by the aloe vera gel group with an average difference (11.71 ± 1.63 mm) and finally the NaCl group with an average difference (9.23 ± 1.81 mm). According to data analysis, on day 7 the NaCl and aloe vera gel groups showed significant differences (p value = 0.043). This is in accordance with Levin's findings which state that aloe vera can help in the burn wound healing process. (Levin et al., 2022).

Data on the percent decrease in burn wound diameter showed that on day 7, the aloe vera gel group experienced the largest decrease of 23.46% and was followed by the *povidone iodine 10%* group with a result of 20.63% and the least was the NaCl group with a result of 13.61%. However, on day 14 the *povidone iodine 10%* group experienced the greatest decrease with a result of 59.29% and the aloe vera gel group as much as 50.96%. This data shows that the use of aloe vera gel is more effective on day 7 than day 14.

Data analysis of the percent decrease in wound diameter showed the same results as the burn diameter data analysis. On day 7, the aloe vera gel and NaCl groups had a significant difference (p value = 0.022). On day 14, the group that had a significant difference was the *povidone iodine 10%* group with the NaCl group (p value = 0.017).

However, at both times, the comparison between the aloe vera gel and *povidone iodine 10%* groups showed no significant difference (p value = 0.691 and 0.380). These results can be obtained because the two groups tend to have similar effects, both reducing the diameter of the burn wound.

The histopathology readings assessed the number of blood vessels, fibroblasts and macrophages as these three parameters are related to the wound healing process. Histopathology on day-0 depicted the least number of blood vessels, fibroblasts and macrophages. This is due to the recent wounding process.

Burn wound healing consists of 3 phases. The first phase of wound healing or inflammation is the initial stage that begins immediately after the burn occurs and lasts for 3-4 days. In this phase, there are changes in the number of blood

vessels. Histopathology images on day 7 showed a slight increase in the number of blood vessels and an increase in cellular activity.

This process involves the release of neutrophilic granulocytes and monocytes (which will later turn into macrophages) from the blood vessels. This triggers phagocytosis activity in the wound area which functions to fight pathogens and clean damaged cells. Macrophages on day 7 increased especially in the aloe vera gel group, stating that the effect of aloe vera is faster in the process of fighting pathogens than other groups. (Fernández-Guarino et al., 2023; I Wayan Suindiana, 2021).

In the proliferation phase, fibroblasts are formed which are responsible for producing collagen. Fibroblasts not only contribute to the formation of granulation tissue but also regulate the movement and proliferation of keratinocytes and play a role in the formation of new blood vessels. From table 4.14 the number of fibroblasts, it can be seen that a drastic increase occurred on day 7. The group with the highest number of fibroblasts is *povidone iodine 10%* which is 127.

In the proliferation phase, phagocytosis by macrophages also occurs. Macrophages and mast cells also actively produce *growth factors* that are important in this phase. Clinically, there will be red granulation tissue, exudate formation and this phase lasts for 3 to 12 days. This is consistent with the finding that the number of macrophages is relatively stable for 14 days. (Fernández-Guarino et al., 2023; I Wayan Suindiana, 2021; Kesehatan et al., 2020)..

The final phase, the maturation or remodelling phase, is characterized by an improvement in collagen structure and a decrease in cell and blood vessel activity. This phase lasts between 3 days to 6 months, and will end when the inflammatory symptoms disappear, characterized by the formation of scar tissue that is thin, pale, soft, and does not cause pain or itching. (Fernández-Guarino et al., 2023; I Wayan Suindiana, 2021).

Based on table 4.18 on day 7, aloe vera gel showed the best results in increasing epidermal thickness. This indicates a faster skin regeneration process compared to the NaCl and *povidone iodine 10%* groups. Although there was a decrease in thickness on day 14, the group given aloe vera gel still showed better thickness than the other groups.

CONCLUSION

This study states that the administration of aloe vera gel as a burn treatment has an effect similar to *povidone iodine 10%*. Based on descriptive data and graphs, it can be concluded that the aloe vera gel group plays the most role on day 7, which is when the inflammatory and proliferation phases take place which is characterized by the number of fibroblasts and macrophages that increase in that group. Fibroblast activity which plays an important role in tissue regeneration and the highest number of macrophages in aloe vera gel on day-7 which plays a role in cleaning wound tissue and supporting regeneration. However, macrophage activity decreased on day-14, indicating that the anti-inflammatory effect of aloe vera gel was optimal up to day 7.

Overall, aloe vera gel was more effective in accelerating wound tissue healing and regeneration on day 7 compared to day 14. On day 14, the effect was still

present but tended to decrease, and *Povidone Iodine* 10% became more effective in supporting continued healing.

REFERENCES

- Alepani, M., Wahyudi, J. T., Tiranda, Y., Health, I. I., Technology, D., Palembang, M., & South, S. (2022). Effectiveness of Aloe Vera Administration on the Burn Wound Healing Process: Literature Review. In *Jurnal Keperawatan Merdeka (Jkm)* (Vol. 2, Issue 1).
- Anggraini, R. W., Saragih, L., & Eka, N. L. (2019). Topical Effects Of Aloe Vera Vegetables Extract Of 10%, And 20% Concentration Toward The Crossoscopic Picture Of Fuel Grade Ii In Rattus Norvercicus Rats Wistar Sheet. In *March* (Vol. 5, Issue 1).
- Aulia, L., & Pane, Y. S. (2022). Effect Of Aloe Vera Extract In Post-Burn Skin Repair In Rats. *F1000research*, *11*, 168. <https://doi.org/10.12688/f1000research.79538.1>
- Fernández-Guarino, M., Hernández-Bule, M. L., & Bacci, S. (2023). Cellular and Molecular Processes in Wound Healing. In *Biomedicines* (Vol. 11, Issue 9). Multidisciplinary Digital Publishing Institute (Mdpi). <https://doi.org/10.3390/biomedicines11092526>
- Hai, Z., Ren, Y., Hu, J., Wang, H., Qin, Q., & Chen, T. (2019). Evaluation Of The Treatment Effect Of Aloe Vera Fermentation In Burn Injury Healing Using A Rat Model. *Mediators Of Inflammation*, *2019*. <https://doi.org/10.1155/2019/2020858>
- Herdawati, T., & Kurniawaty, E. (2019). *Evi Kurniawaty | Mesenchymal Stem Cells as a Therapeutic Breakthrough in Majority Ii Degree Burns | Volume 8/ Number 2 | December*.
- I Wayan Suindiana. (2021). *Nursing Care for Acute Pain in Patient Mr.D with Burns in the Burn Unit Room of Rsup Sanglah Denpasar in 2021*.
- Health, J. I., Husada, S., Agung, G., Yogy, P., & Ananta, V. (2020). Banana Stem Potency (*Musa Pardisiaca* L.) in Burn Wound Healing. *Banana Stem Potency In Burn Wound Healing, Jiksh*, *11(1)*, 334-340. <https://doi.org/10.35816/jiskh.v10i2.283>
- Kim, H., Shin, S., & Han, D. (2022). Review Of History Of Basic Principles Of Burn Wound Management. In *Medicina (Lithuania)* (Vol. 58, Issue 3). Mdpi. <https://doi.org/10.3390/medicina58030400>
- Lepelletier, D., Maillard, J. Y., Pozzetto, B., & Simon, A. (2020). *Povidone Iodine: Properties, Mechanisms Of Action, And Role In Infection Control And Staphylococcus Aureus Decolonization*. <https://doi.org/10.1128/Aac>
- Levin, N. J., Erben, Y., Li, Y., Brigham, T. J., & Bruce, A. J. (2022). A Systematic Review And Meta-Analysis Comparing Burn Healing Outcomes Between Silver Sulfadiazine And Aloe Vera. *Cureus*. <https://doi.org/10.7759/cureus.30815>
- Muhammad, S., Haikal, S., & Susilo, A. P. (2021). Continuity of Care and Prevention of Complications in Burns. In *J. Ked. Mulawarman* (Vol. 8, Issue 1).

- Nelky Suriawanto, Evi Setyawati, & Narwan. (2021). *Effect of Stingless Bee Propolis Extract on the Healing of White Rat Burns (Rattus Norvegicus)*. 8(1).
- Opriessnig, E., Luze, H., Smolle, C., Draschl, A., Zrim, R., Giretzlehner, M., Kamolz, L. P., & Nischwitz, S. P. (2023). Epidemiology Of Burn Injury And The Ideal Dressing In Global Burn Care - Regional Differences Explored. In *Burns* (Vol. 49, Issue 1, Pp. 1-14). Elsevier Ltd. <https://doi.org/10.1016/j.burns.2022.06.018>
- Prasetya, A., & Suhaymi, E. (2020). Comparison of the Effectiveness of Povidone Iodine 10% with Date Palm Juice on the Duration of Burn Healing in White Rats (*Rattus Norvegicus*.L) Wistar Male. *Pandu Husada Journal*, 1(3), 178. <https://doi.org/10.30596/jph.v1i3.4909>
- Prasongko, E. T., Lailiyah, M., Muzayyidin, W., Pharmacy, S., Pharmacy, F., Health, I., & Wiyata, B. (2020). *Formulation And Effectivity Testing Of Ambarella (Spondias Dulcis F.) Leaves Extract Gel Against Burns In Wistar Rats (Rattus Novergicus)*. 7(1).
- Research, A., Akbar, A., Azis, K., Gani, B., Wahab, M. I., Syahril, E., & Hasbi, B. E. (2023). Fakumi Medical Journal Comparison of the Use of Betel Leaf (*Piper Betle L*) and Povidone Iodine on Wound Healing. *Fakumi Medical Journal: Journal of Medical Students*, 2(12), 2022.
- Tammam, B. M. H., Habotta, O. A., El-Khadragy, M., Abdel Moneim, A. E., & Abdalla, M. S. (2023). Therapeutic Role Of Mesenchymal Stem Cells And Platelet-Rich Plasma On Skin Burn Healing And Rejuvenation: A Focus On Scar Regulation, Oxido-Inflammatory Stress And Apoptotic Mechanisms. *Heliyon*, 9(9). <https://doi.org/10.1016/j.heliyon.2023.E19452>
- Tuti Sulastri, Rika Safitri, & Natasya Luzien. (2022). *Health Education on First Aid for Burns (Combustio) to Members of Dharma Wanita Persatuan Sultan Ageng Tirtayasa University*. 1(1), 30-33.
- Uswatun Hasanah, Andi Alamsyah Irwan, & Rusli Malli. (2023). *Level of Knowledge about Burns Management in the Medical Assistance Team*. 2(2).