

COMPARISON OF THE EFFECTIVENESS OF GRAPE SEED (*Vitis Vinifera*) WITH ALOE VERA (*Aloe Vera*) IN THE REPAIR OF BURNS IN WISTAR RATS BASED ON WOUND DIAMETER

Yashinta Maria Veronica¹, Oliviti Natali², Djohan³

Universitas Prima Indonesia¹²³

Email: yashintaamaria29@gmail.com¹, olivitinatali@unprimdn.ac.id²,

djohan@unprimdn.ac.id³

ABSTRACT

Burns are tissue damage or loss caused by contact with heat sources such as fire, hot water, chemicals, electricity and radiation. The grape plant has an activity of pharmacological effects, which are mainly present in its seeds and fruits. Grape seed extract containing proanthocyanidin can help wound healing by promoting neovascularization, extracellular matrix remodeling, fibroblastic cell migration and differentiation. Aloe vera leaves can be used to treat skin lesions, such as burns, irradiation damage and ischemic ulcers. In addition to being a hydrating and skin-protecting agent, this gel also has healing, analgesic, and anti-inflammatory activities because aloe vera contains vitamins C and E, essential amino acids, and polysaccharides that stimulate tissue growth and cell regeneration. The objective is to determine the effectivity of burn wound repair using grape seed extract and aloe vera. This research used 24 white rats weighing 150 to 200g that divided into 4 groups, positive control group, negative control group, 10% grape seed extract treatment group, and 10% aloe vera extract treatment group. This study used an experimental method with True Experimental design with Randomized Post-test only Control Group Design, by giving 10% concentration of grape seed extract and aloe vera extract with 10% concentration to rats that has been burnt. The statistical analysis result of burn wound cureness among rats that have given grape seed extract and aloe vera obtained from group K of 8.42 mm, followed by the P0 group of 13.07 mm, the P1 group of 10.1 mm, and the P2 group of 9.31 mm.. The data was analyzed using the One Way Anova test and showed that there was significant effect with a p value of 0.000. Grape seed extract and aloe vera with a concentration of 10% have the potential in healing burn wounds that have been shown at the examination graphic. The greatest potential for healing burns is the aloe vera extract group with 10% concentration.

KEYWORDS Grape seed extract, aloe vera extract, burns, wistar rats, wound diameter

How to cite: Veronica Y.M et al. (2024). Profile Of Oral Corticosteroid Use In Patients In Madiun City Pharmacies. Journal Eduvest. 4(11): 8097-8102
E-ISSN: 2775-3727



This work is licensed under a Creative Commons Attribution-ShareAlike 4.0 International

INTRODUCTION

The skin is an organ of the human body located in the outermost part. The skin has a function to protect parts of the body from various kinds of disorders and stimuli from the outside. As a protector, the skin often suffers damage due to external hazards, one of which is burns (Prasongko et al., 2020).

The skin is an indispensable vital organ and a mirror of health and life. The skin is also very complex, elastic and sensitive. The most common skin problem is wounds. Any skin integrity disorder, such as burns and open wounds, can cause impaired body function and even death (Agungpriyono et al., 2020).

Burns can occur as a result of direct or indirect fireburns, including sunlight and chemicals. Burns can cause parts of the skin tissue to peel off, releasing water and serum. This condition can cause the pathogen to develop on the burn and take a long time for the skin tissue to close again until it heals. (Suriawanto, 2021).

Burns require immediate treatment because they are at high risk of causing infection that can hinder the healing process. Several topical preparations for burns have been circulated. These topical preparations generally contain synthetic medicinal ingredients. There are several risks of using synthetic chemical drugs in the treatment of burns, including allergies and hypersensitivity (Putra & Erliana, 2022).

The goal of burn treatment is to prevent infection, stimulate collagen formation to allow the development of epithelial cell residues to cover the surface of the wound (Hutauruk et al., 2022).

Indonesia is a country known for its abundant biodiversity, where there are a lot of plants that can be used as medicine. Currently, traditional or herbal medicine has begun to be widely used by the community. Herbal plants are valuable plants because of their taste, aroma, and function that can be used for cooking and as medicine. Treatment using medicinal plants or herbs also has the advantage of not causing side effects that are too high when compared to medical drugs (Laguliga et al., 2021).

Grapes (*Vitis vinifera* L.) are one of the fruit crops in the world with a high production rate, which is around 75 million tons/year. About 50% of wine production is used to make wine, one-third is consumed as fresh fruit, and the rest is marketed in the form of dried fruit or can be made into fruit juice (non-fermented). Grapes are known to contain many nutrients, such as vitamins, minerals, carbohydrates, fiber, and phytochemical compounds. Phytochemical compounds that are widely found in grapes are polyphenols that play an important role in health, one of which is as an antimicrobe (Stress et al., 2023).

Grapes contain phytochemicals contained in the skin, fruits, especially in grape seeds. Among others, there is a group of 5-8% polyphenols in the form of resveratrol, tannins, flavonoids, quercetin, catechins, pectins, tannins and anthocyanins which have various properties, including preventing fungal

infections. Wine contains a variety of vitamins, carotenoids and polyphenol compounds. Grape seed extract is a source of proanthocyanidins that have 20 times more antioxidant power than vitamin C and 50 times more than vitamins. So that this content is good for helping wound healing by increasing local neovascularization, extracellular matrix remodeling, migration, and differentiation of fibroblastic cells (Martín Rubio et al., 2020).

A clinical trial conducted by Hematti et al, showed that after 3 days of treatment, the size of burns in the group that received grape seed extract was reduced compared to the placebo group. On the seventh day of the study regardless of non-healing from all groups receiving grape seed extract, there were 20 cases of 31 (64.5%) who had fully recovered and there was only a slight visible erythema at the site of the wound (Firdaus et al., 2020).

Based on literature searches, the results of research on grape plants have pharmacological effect activities, which are mainly found in the seeds and fruits, including antibacterial, antifungal, anticancer, antioxidant and antihyperlipidemia. The use of grape seed extract of 6.5% was effective in increasing collagen crosslinking. Grape seed extracts containing proanthocyanidins may also aid wound healing by improving local neovascularization, extracellular matrix remodeling, migration and differentiation of fibroplastic cells (Khairunnisa et al., 2022).

Another alternative herbal medicine that can be used as a burn remedy is aloe vera. Aloe vera (Aloe vera) is a semi-tropical plant that has a long history and is ranked highly as a versatile herbal plant, the characteristics of aloe vera are thick, tapered leaves, have short stalks from the ground. Aloe vera is not included in the cactus group, but belongs to the lily tree family, known as aloe barbadensis (Alepandi et al., 2022).

To achieve rapid formation of the integrity of damaged tissues and reduce the development of fibrosis and hypertrophic scars, the application of therapeutic agents to modulate the healing process, including those that occur naturally. One of the agents that can be used is aloe vera. Aloe vera therapy can be used to treat skin lesions, such as burns, irradiation damage, and ischemic ulcers. Apart from being a powerful hydrating and protective agent for the skin, this gel also has healing, analgesic, and anti-inflammatory activities. Aloe vera also contains vitamins C and E, essential amino acids, and polysaccharides that stimulate tissue growth and cell regeneration (Wardani, 2020).

A study conducted by Atika Rahmi in 2020 compared the effectiveness of 1% Silver sulfadiazine (SSD) cream with 99% aloe vera gel that will be tested on 9 male rats. The results obtained in this study where the administration of aloe vera gel has a very good effect on the proliferation phase and the wound contraction process, and plays an important role in reducing and narrowing the size of the wound margin in wistar rats. The mucus produced from aloe vera not only increases the amount of collagen at the wound site, but also increases the transverse connections between the ties thereby accelerating repair. In the study group, aloe vera gel treatment group 99% narrowed the burn surface area faster compared to SSD 1% on day 14. This proves that the administration of aloe vera gel is effective in inhibiting bacterial growth by determining the diameter of the inhibition zone

against *Escherichia coli* and *Staphylococcus aureus* bacteria (Hasbi & Waspodo, 2024).

Grape seeds and aloe vera as a burn dressing or burn treatment have not been proven effective or have not been compared, therefore it is necessary to conduct research on the effectiveness of burn treatment using grape seeds and aloe vera using rat media.

RESEARCH METHODS

The type of research used in this study is an experimental study with a True Experimental design with a Randomized Post-test only Control Group Design using white male wistar rats as experimental animals used. The treatment group is called the experimental group, and the group that is not treated is called the control group.

- 1) Target population: Wistar type white rats with healthy males.
- 2) Affordable population: Wistar white rats with healthy males and a weight of 150-200 grams.

The sample to be used in this study is a white rat (*Rattus norvegicus*) of the wistar strain type which was selected with the following criteria:

- a. Adult age 75-90 days
- b. Male
- c. Normal average weight 150-200 grams
- d. Healthy

Wistar rats have several advantages over small rats, namely easier to reproduce, easier to genetically manipulate, easier to observe because they are less aggressive and more proportional. In addition, mice are biologically similar to humans and have a similar biological response to humans.

Just like humans, the surface of mice is also covered with skin. The skin of mice consists of five main layers, namely the epidermis, dermis and subcutaneous tissue (white adipose tissue), Panniculus carnosus and adventitia (subcutaneous tissue). Unlike human skin, the rat epidermis consists of the upper layers: the stratum basale, the spinosum, and the corneum (Naldaiz-Gastesi et al., 2018).

The sample is part of the number and characteristics possessed by the population (Sugiyono, 2020). In this study, the sample size was determined using Federer's formula, namely:

$$(n-1)(T-1) \geq 15$$

$$(n-1)(4-1) \geq 15$$

$$(n-1) \geq 3/15$$

$$n-1 \geq 5$$

$$n \geq 6$$

Information:

Q: Number of treatment groups

N: Sample size

From this formula $(n) = 6$, the minimum number of mice needed for each group is 6. This study used a total of 24 mice divided into 4 groups.

Comparison of The Effectiveness of Grape Seed (*Vitis Vinifera*) With Aloe Vera (Aloe Vera) in The Repair of Burns in Wistar Rats Based on Wound Diameter

The sample carried out in this study is seeds from grapes which will then be separated between the fruit and the grape seeds. After the grape seeds are separated from the fruit, they are then washed and then dried in the dryer. After the grape seeds are dry, they are then mashed using a blender until powder is formed. The manufacture of grape seed ethanol extract was carried out by maceration method using 70% ethanol. A total of 150 grams of grape seed powder is macerated with a ratio of 1:10 powder to solvent. Covered and stored in a place away from light for five days while stirring every 6 hours. After that, the pulp is filtered and squeezed so that maserat I is produced.

Maserat I and II are then combined and stored in a cool place protected from direct light for two days, until the maserat obtained becomes clear as a sign that the compound is attracted to all. The filtrate results obtained are evaporated using a rotary evaporator with a temperature of no more than 50°C to produce a thick extract (Mikraj, 2024).

The manufacture of aloe vera extract used is fresh aloe vera leaves in dark green. The manufacture of aloe vera leaf extract is carried out by maceration method which aims to separate the active compounds contained in aloe vera using a 70% ethanol solvent to avoid the decomposition of compounds due to heat. Aloe vera is washed and then drained, peeled and separated between the skin and leaves from the aloe vera flesh. Then the aloe vera meat is cut into small pieces and mashed using a blender. The purpose is to be smoothed so that the contact of the surface of the powder and solvent is greater so that the chemical compounds contained in aloe vera can be extracted easily. Maceration was carried out by inserting 1000 grams of aloe vera by adding 70% ethanol solvent to the simplicia sample and then stirring for the first 6 hours. Let stand for 18 hours while stirring occasionally. Then filter the maserat I using cotton and filter paper. Repeat the extraction process on the pulp using 2 liters of 70% ethanol so that maserat II can be produced. Polar ethanol solvents can attract polar compounds such as alkaloids, flavonoids, tannins, saponins, phenolics and other polar compounds. The whole maserat or liquid extract will be evaporated by vacuum rotary evaporatory with a heating temperature of 40-50°C until a thick aloe vera meat extract is obtained. After that, the two extracts will each be divided into a 10% concentration (Abidin et al., 2021).

RESULT AND DISCUSSION

Skrining Confidence

The initial stage of this study was a phytochemical screening test from grape seed and aloe vera samples which aimed to analyze the phytochemical content contained in the samples, the results of the screening can be seen in the following table.

Table 1. Results of Phytochemical Screening of Grape Seed Extract Gel

Metabolite Seconds	Result
Flavanoid	+
Alkaloid	-
Saponin	+
Tannin	+

Glikosida	+
Steroid/ Triterpenoid	+

In the phytochemical screening test table above, it can be seen that grape seed gel extract contains secondary metabolites, namely: Flavonoids, saponins, tannins, glycosides, and triterpenoids.

Table 2. Phytochemical Screening Results of Aloe Vera Gel Extract

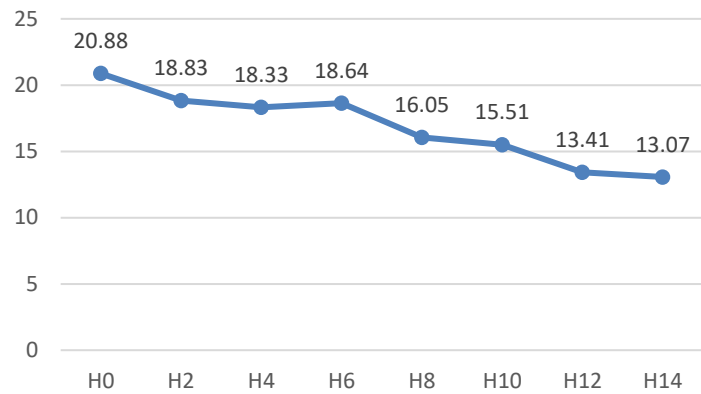
Metabolite Seconds	Result
Flavanoid	+
Alkaloid	+
Saponin	+
Tannin	+
Glikosida	+
Steroid/Triterpenoid	+

Wistar Burn Diameter

The diameter of the wound in wistar rats was given after anesthesia with ketamine at a dose of 20mg/KgBB intramuscular route. The first step, by shaving the fur on the back of the rat \pm 3 cm long, then cleaning it with a cotton swab of 70% alcohol. Next, apply a burn using a 20 mm diameter brass metal that has been soaked in boiling water at a temperature of 100°C for \pm 3 minutes, then exposed to the surface of the rat skin. This treatment is carried out on each test animal. The following are the results of observations of burn diameter in rats.

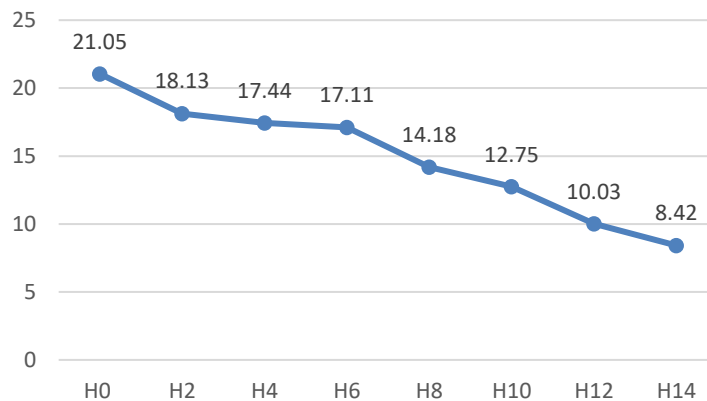
Table 3. Observation Results of Burn Diameter

Group	Burn Diameter (mm)							
	H0	H2	H4	H6	H8	H10	H12	H14
P0	20.88	18.33	18.33	18.64	16.05	15.51	13.41	13.07
K	21.05	18.13	17.44	17.11	14.18	12.75	10.03	8.42
P1	20.78	18.34	17.28	17.36	14.37	12.9	11.29	10.1
P2	21.53	19.03	17.78	17.98	14.21	13.72	11.32	9.32



Picture 1. Negative Control Burn Diameter

Based on the graph of the wound diameter of the negative control group above, it shows that there is a decrease in the diameter of the burn starting from the time of surgery until the 14th day. On H0 the diameter of the wound was 20.88 mm, on the 2nd day the remaining wound was 18.83 mm, on the 4th day the remaining wound was 18.33 mm, on the 6th day the remaining wound was 18.64 mm, on the 8th day the remaining wound was 16.05 mm, on the 10th day the remaining wound was 15.51 mm, on the 12th day the remaining wound was 13.41 mm, until the 14th day there was still a wound of 13.07 mm, which means that the wound had not closed completely.



Picture 2. Burn Diameter of Positive Control Group (Burnazin)

Based on the graph of the wound diameter of the positive control group given burnazine ointment above, it shows that there is a decrease in burn diameter starting from the time of surgery until the 14th day. On H0 the diameter of the wound was 21.05 mm, on the 2nd day the remaining wound was 18.13 mm, on the 4th day the remaining wound was 17.44 mm, on the 6th day the remaining wound was 17.11 mm, on the 8th day the remaining wound was 14.18 mm, on the 10th day the remaining wound was 12.75 mm, on the 12th day the remaining wound

was 10.03 mm, until the 14th day there was still a wound of 8.42 mm which means that the wound had not closed completely.

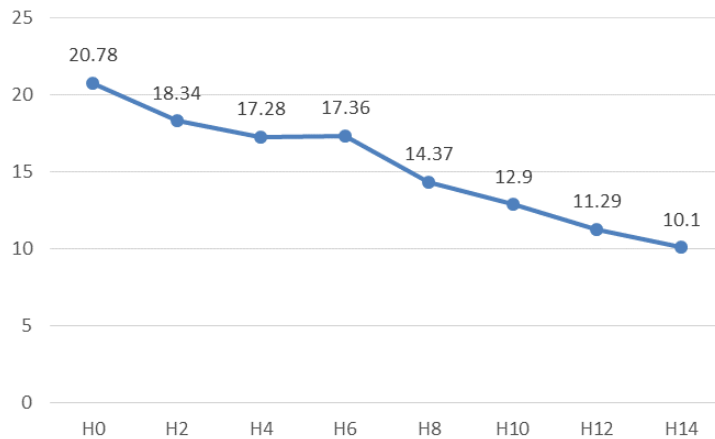
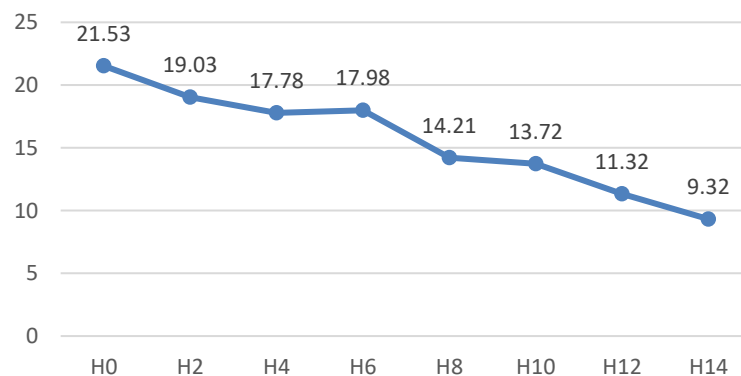


Figure 3. Burn Diameter Group Grape Seed Extract Gel

Based on the graph of the wound diameter of the group given grape seed gel extract above, it shows that there is a decrease in burn diameter starting from the time of surgery until the 14th day. On H0 the diameter of the wound was 20.78 mm, on the 2nd day the remaining wound was 18.34 mm, on the 4th day the remaining wound was 17.28 mm, on the 6th day the remaining wound was 17.36 mm, on the 8th day the remaining wound was 14.37 mm, on the 10th day the remaining wound was 12.9 mm, on the 12th day the remaining wound was 11.29 mm, until the 14th day there was still a wound of 10.1 mm, which means that the wound had not closed completely.



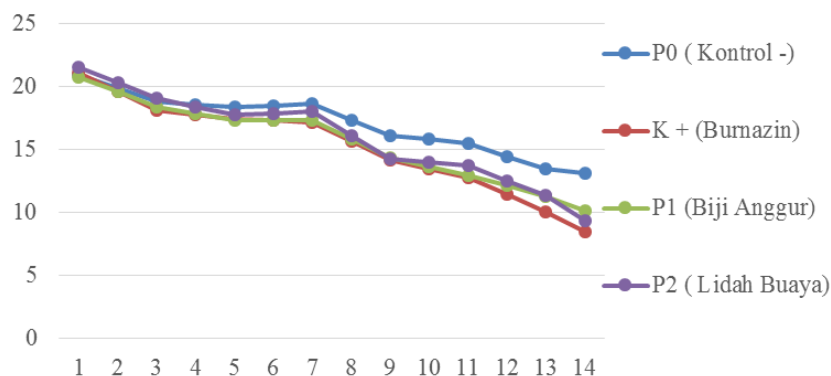
Picture 4. Burn Diameter of Aloe Vera Gel Extract Group

Based on the graph of the wound diameter of the group given aloe vera gel extract above, it shows that there is a decrease in the diameter of the burn starting from the time of surgery until the 14th day. On H0 the diameter of the wound was 21.53 mm, on the 2nd day the remaining wound was 19.03 mm, on the 4th day the remaining wound was 17.78 mm, on the 6th day the remaining wound was 17.98 mm, on the 8th day the remaining wound was 14.21 mm, on the 10th day the remaining wound was 13.72 mm, on the 12th day the remaining wound was 11.32 mm, until the 14th day there was still a wound of 9.32 mm, which means that the wound had not closed completely.

Comparison of The Effectiveness of Grape Seed (*Vitis Vinifera*) With Aloe Vera (*Aloe Vera*) in The Repair of Burns in Wistar Rats Based on Wound Diameter

remaining wound was 13.72 mm, on the 12th day the remaining wound was 11.32 mm, until the 14th day there was still a wound of 9.32 mm which means that the wound had not closed completely.

Below is a summary graph of burn diameters in 4 sample groups in the study.



Picture 5. Graph of burn diameters in 4 sample groups

Based on the table and graph of the observations above, on the 14th day it was known that the burns on the wistar given burnazin ointment had the smallest wound diameter compared to the other 3 sample groups, which was 8.42 mm. This occurs due to the antibacterial activity produced by burnazin containing sulfonamides. Furthermore, the second smallest decrease in wound diameter was the aloe vera gel extract group with a result of 9.32 mm. Then for the group that was given grape seed gel extract, the result was 10.1 mm. This also proves that the phytochemical content contained in grape seeds can provide a healing effect on burns even though it is not optimal.

Furthermore, data analysis was carried out with the aim of testing whether there was a difference in the diameter of burns in wistar rats, between grape seed extract samples, aloe vera extract, the positive control group given burnazin ointment and the negative control group. The test used is a one-way anova test if the research data is normally distributed data and has a homogeneous variance. The following are the results of normality and homogeneity test data.

Table 4. Normality and Homogeneity

Parameter	Treatment	P Value	Result
Burn Diameter	P0	0.33	Normal
	K	0.02	Abnormal
	P1	0.59	Normal
	P2	0.42	Normal
Levene Test homogeneity		0.14	Homogeneous

Saphiro wilk P > 0.05

Levene Test P > 0.05

Based on the data in the table above, it can be seen that the P Value of burn diameter data in all tested sample groups is >0.05 , this shows that the distribution of wound diameter data is normal, except for the positive control group given burnazin. The results of the variance test obtained a Levene Test value of 0.14 which means >0.05 , it can be interpreted that the data is homogeneous. Furthermore, the burn diameter data was analyzed with the Oneway Anova test which can be seen in the table below.

Table 5. Comparison of Burn Diameter

Group	Mean \pm SD	P Value
P0	1.07 pm \pm 2.73 pm	0.000
K	8.42 \pm 1.85	
P1	10.1 \pm 0.59	
P2	9.32 \pm 1.64	

One way anova $p < 0.05$

Post hoc benferroni

Based on the results of the above test, a P Value of 0.000 was obtained, which means <0.05 , so there was a significant difference in the diameter of the burn between the negative control sample group, the positive control given burnazin ointment, grape seed gel extract and aloe vera gel extract. Wistar rats given burnazin ointment were known to have the smallest wound diameter when compared to the other 3 sample groups with an average wound diameter of 8.42 mm, followed by the group that received aloe vera gel extract of 9.31 mm, then the grape seed gel extract group of 10.1 mm, and the average burn diameter was the largest found in the negative sample group with a result of 13.07 mm.

Percentage Decrease in Burn Diameter

Based on the observation data of burn diameter that has been described above, the next way to find out the difference in the effectiveness of each treatment is to measure the percentage of reduction in wound diameter among 4 sample groups. The following is data on the percentage reduction in wound diameter in 4 sample groups in the study.

Table 6. Data Results of Percentage Reduction in Burn Diameter

Group	Percentage of Reduction in Burn Diameter						
	H2	H4	H6	H8	H10	H12	H14
P0	9.8	12.83	14.69	24.27	26.16	35.67	37.61
K	13.94	17.23	18.98	32.8	39.59	52.34	60.1
P1	11.7	16.75	16.38	30.81	37.9	45.62	51.34
P2	11.75	17.58	16.21	33.82	35.99	47.17	56.29

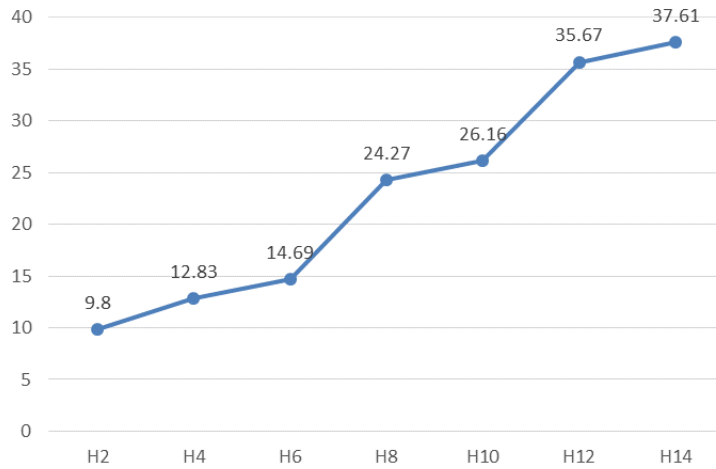


Figure 6. Negative Control Burn Diameter Reduction Percentage

Based on the percentage graph of the negative control group above, it shows that there is an increase in the percentage of reduction in burn diameter from the day of surgery to the 14th day. On the 2nd day it decreased by 9.8%, on the 4th day it decreased by 12.83%, on the 6th day it decreased by 14.69%, on the 8th day it decreased by 24.27%, on the 10th day it decreased by 26.16%, on the 12th day it decreased by 35.67%, and until the 14th day it decreased by 37.61% from the condition on the day of surgery.

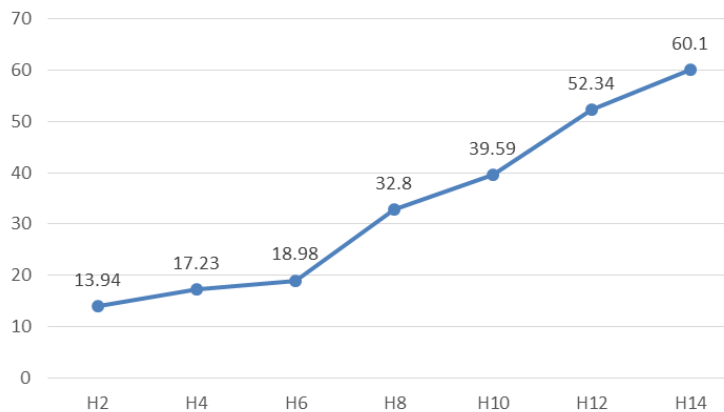


Figure 7. Percentage decrease in the diameter of positive control burns (Burnazin)

Based on the percentage graph of the group given burnazin above, there was an increase in the percentage decrease in wound diameter from the day of surgery to the 14th day. On the 2nd day it decreased by 13.94%, on the 4th day it decreased by 17.23%, on the 6th day it decreased by 18.98%, on the 8th day it decreased by 32.8%, on the 10th day it decreased by 39.59%, on the 12th day it decreased by 52.34%, and until the 14th day it decreased by 60.1% from the condition on the day of surgery.

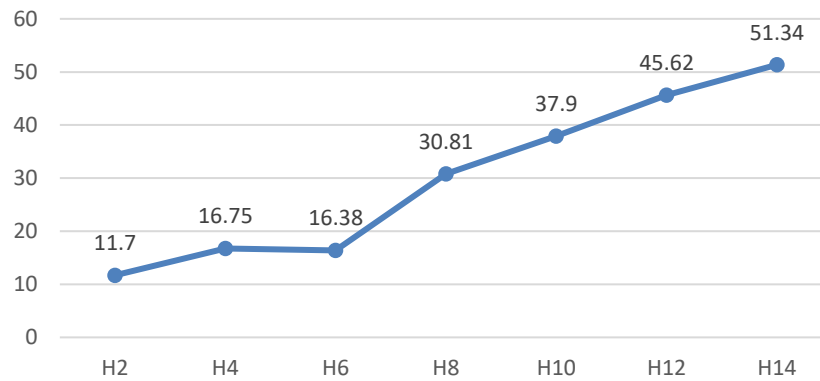
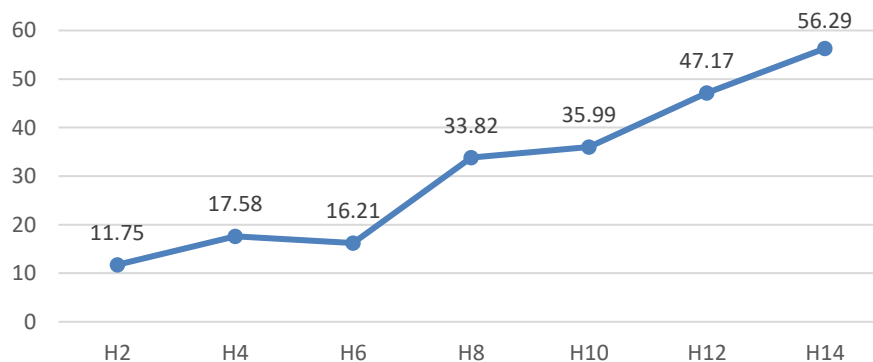


Figure 8. Percentage Reduction in Burn Diameter of Grape Seed Gel Extract Group

Based on the percentage graph of the group given grape seed gel extract above, it shows that there is an increase in the percentage of decrease in wound diameter from the day of surgery to the 14th day. On the 2nd day it decreased by 11.7%, on the 4th day it decreased by 16.75%, on the 6th day it decreased by 16.38%, on the 8th day it decreased by 30.81%, on the 10th day it decreased by 37.9%, on the 12th day it decreased by 45.62%, and until the 14th day it decreased by 51.34% from the condition on the day of surgery.



Picture 9. Percentage Decrease in Burn Diameter of Aloe Vera Gel Extract Group

Based on the percentage graph of the group given aloe vera gel extract above, it shows an increase in the percentage decrease in wound diameter from the day of surgery to the 14th day. On the 2nd day it decreased by 11.75%, on the 4th day it decreased by 17.58%, on the 6th day it decreased by 16.21%, on the 8th day it decreased by 33.82%, on the 10th day it decreased by 35.99%, on the 12th day it decreased by 47.17%, and until the 14th day it decreased by 56.29% from the condition on the day of surgery.

Below is a summary graph of the percentage reduction in burn diameter in 4 sample groups in the study.

Comparison of The Effectiveness of Grape Seed (*Vitis Vinifera*) With Aloe Vera (*Aloe Vera*) in The Repair of Burns in Wistar Rats Based on Wound Diameter

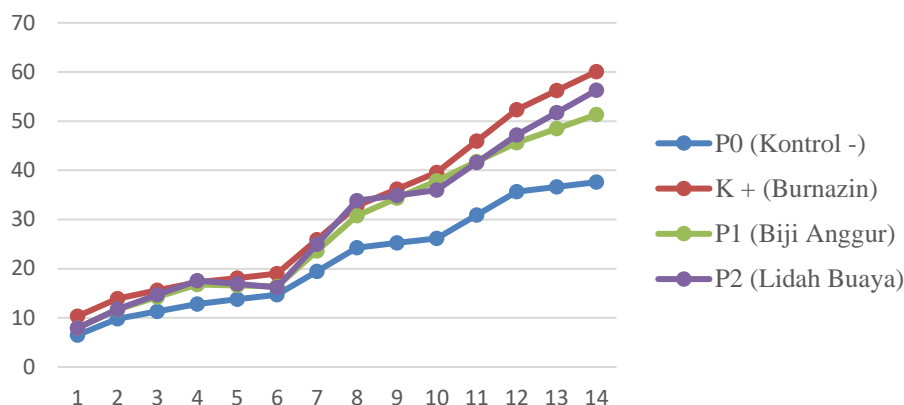


Figure 10. Summary of Percentage Reduction in Burn Diameter in 4 Sample Groups

Based on the table and graph above, on the 14th day it was shown that the burns on the wistar given burnazin ointment had the largest percentage of burn diameter compared to the other 3 sample groups, which was 60.1%. Furthermore, the second largest percentage decrease was found in the aloe vera gel extract group of 56.29%. Then the group given grape seed gel extract got a result of 51.34%, and for the smallest percentage reduction in burn diameter was the negative control group with a result of 37.61%.

The next analysis was to test whether there was a difference in the percentage reduction in burn diameter in wistar rats, between grape seed extract samples, aloe vera extract, the positive control group given burnazin ointment, and the negative control group. The test used is a one-way anova test if the research data is normally distributed data and has a homogeneous variance. The following are the results of normality and homogeneity test data.

Table 7. Normality and Homogeneity

Parameter	Treatment	P Value	Result
Percentage Decrease in Burn Diameter	P0	0.817	Normal
	K	0.310	Normal
	P1	0.108	Normal
	P2	0.672	Normal
Levene Test homogeneity		0.246	Homogeneous

Saphiro wilk $P > 0.05$
 Levene Test $P > 0.05$

Based on the data in the table above, it can be seen that the P Value of the percentage decrease in burn diameter in all groups of samples tested is >0.05 , this shows that the distribution of the percentage data is normal. The results of the variance test obtained a Levene Test value of 0.246 which means >0.05 , it can be interpreted that the data is homogeneous. Furthermore, the data on the percentage reduction in burn diameter was analyzed with the Oneway Anova test which can be seen in the table below.

Table 8. Comparison of Percentage Reduction in Burn Diameter

Group	Mean ± SD	P Value
P0	37.6 ± 14.4	0.000
K	60.1 ± 8.06	
P1	51.3 ± 3.08	
P2	56.3 ± 9.47	

One way anova $p < 0.05$

Post hoc benferroni

Based on the results of the above test, a P Value of 0.000 was obtained, which means < 0.05 , so there was a significant difference in the percentage of reduction in burn diameter between the negative control sample group, the positive control given burnazin ointment, grape seed gel extract and aloe vera gel extract. Wistar rats given burnazine ointment were known to have the highest average percentage reduction in burn diameter when compared to the other 3 sample groups, which was 60.1%, followed by the group that gave aloe vera gel extract by 56.3%, then the grape seed gel extract group by 51.3%, and the lowest average percentage of reduction in wound diameter was found in the negative sample group with a result of 37.6%.

Based on the results of the phytochemical screening obtained, it shows that grape seed extract contains phenolic compounds, flavonoids, saponins, tannins and triterpenoids. The results of this study are in line with the research conducted by Syafriana et al, which stated that grape seed ethanol powder and extract contain phenolic compounds, flavonoids, saponins, tannins and triterpenoids. So that some of these metabolite compounds are compounds that have the potential to be antimicrobials found in grape seeds (Syafriana et al., 2020).

The results of the phytochemical screening test of aloe vera ethanol extract can be found to contain the same active compounds, this is in accordance with research (Septiawan et al., 2020) that aloe vera ethanol extract contains phenolic compounds, flavonoids, alkaloids, saponins, tannins, and triterpenoids.

The content of metabolite compounds has their respective functions in preventing secondary infections and as anti-inflammatory. Research conducted by Aulia et al, states that the content of flavonoids can inhibit and kill bacteria that infect wounds. Flavanoids also function in the wound healing process. Flavanoids work by impairing the permeability of bacterial cell walls, microsomes and lysosomes as a result of the interaction between flavonoids and bacterial DNA. Flavanoids have anti-inflammatory activity that functions as anti-inflammatory, preventing stiffness and pain, so that they can reduce inflammation and help reduce pain in the event of bleeding or swelling in the wound (Aulia et al., 2024).

Steroid secondary metabolite compounds also work as anti-inflammatory because they have the ability to prevent the formation of arachidonic acid by inhibiting phospholipase A2. Triterpenoids work in accelerating the healing process by stimulating the manufacture of extracellular matrices and encouraging an increase in the percentage of collagen present in fibronectin cells. Thus, this mechanism proves the existence of bacteriostatic and bactericidal abilities

Comparison of The Effectiveness of Grape Seed (*Vitis Vinifera*) With Aloe Vera (*Aloe Vera*) in The Repair of Burns in Wistar Rats Based on Wound Diameter

contained in steroid/triterpenoid metabolite compounds (Lutfiah et al., 2023). The screening results showed positive tannins, which means that tannin compounds act as antibacterial agents and astringents in soothing gels that work by shrinking open skin pores due to irritation. In addition, the test results of saponins were positive, because this compound works as an antioxidant and cleansing agent in soothing gels. Saponins play a role in cleaning the surface of the skin that is irritated, reddened and wounded, thus preventing the growth of microbes. This compound also has a function to ward off free radicals that can damage skin health. The content of alkaloid compounds contained in aloe vera extract functions in stimulating the speed of wound healing by increasing Transforming Growth Factor $\alpha 1$ (TGF $\alpha 1$) and Epidermal Growth Factor (EGF). It is also known that alkaloids have the potential to increase hair growth, nervous system stimulants, cough medicines, eye drops, sedatives, anticancer, and antibacterial (Prastyoningsih et al., 2024).

In the winemaking industry, grape residues and residues, including seeds and pulp are an interesting product given the health benefits of the components they contain. One of them is the phenolic component found in grape seed extract which has antioxidant and antimicrobial activity. Due to this activity, grape seed extract which is rich in phenolic compounds can also be used for the food industry, namely as a natural additive in preventing microbial growth and lipid oxidation. The benefits of grape seeds in healing skin disorders, bone healing and the presence of photoprotector activity have been reported. In addition, some research evidence also shows that grape seed extract provides anti-cancer chemoprevention and protection for the heart. In systemic conditions, neuroprotective effects, reducing brain damage, as well as anti-apoptotic activity and proteome preservation have been demonstrated by (Martín Rubio et al., 2020) in studies conducted on animals treated with grape seed extract. Another role of grape seed extract is also known to reduce inflammation and delay the development of Alzheimer's and act as a neuroprotective agent in Parkinson's disease.

The anti-inflammatory and antioxidant effects resulting from grape seed extract have been proven in various studies in the reduction of inflammatory mediators such as IL6, and TNF α . Phenolic compounds are one of the secondary metabolites that are most responsible for this effect. In the healing of wounds due to surgery, it is also proven due to the presence of proanthocyanidins and flavonoids found in grape seed extract (Taype-Rondan et al., 2017). Although the results of this study are promising, the use of grape seed extract for humans is still a controversial topic because there have not been many studies that have reported clear conclusions. However, some results from animal or human trials prove that grape seed extract can be an efficient source of antioxidants.

Meanwhile, the use of aloe vera plants is not only as an ornamental plant, but is used as medicine and raw materials in the cosmetics industry. One of the specialties of aloe vera is that all parts of the plant can be used. This can be ascertained because the gel properties contained in aloe vera are able to penetrate into the skin, thereby inhibiting the loss of too much fluid from the skin. In the wound healing process, it can be divided into three main phases, which consist of hemostasis and inflammation, proliferation and maturation and remodelling.

Wound healing can be assisted by natural remedies by administering aloe vera gel topically which has been researched to accelerate wound healing due to the stimulation of aloe vera against the proliferation of several types of cells. This statement is in line with research (Ningsih & Ambarwati, 2021) which explains that in total burns, aloe vera provides a beneficial effect by significantly reducing inflammation so that it can heal and also disguise scars.

The protease and glucomannan enzymes found in aloe vera can provide antibacterial and antifungal effects, so it can stimulate fibroblasts in healing burns. The enzymatic system of antioxidants in the form of glutathione peroxidase and superoxide dismutase also accelerates wound healing by neutralizing the effects of free radicals produced by wounds. The content contained in aloe vera mucus consisting of glycoproteins and polysaccharides can prevent pain inflammation, accelerate wound repair and skin growth. In addition, vitamins E and C, as well as several amino acids also play an important role in accelerating wound healing. This is proven in research conducted by (Maternity, 2022).

Burn treatment needs to be carried out immediately so that the wound healing process is not delayed and does not result in infection. The most commonly used and known treatment as the gold standard for burns is the administration of a topical antimicrobial called silver sulfadiazine. The resulting antibacterial activity comes from superficially acting silver ions with limited penetration rates. The activity produced by the silver ion works through increased permeability of bacterial cell walls through disruption of DNA replication, direct modification of lipid cell membranes or the formation of free radicals (Iga et al., 2018).

CONCLUSION

From the results of this study, it was found that grape seed extract and aloe vera were effective for healing burns according to the data that had been distributed normally and had the same variant, so that from the table of the results of the One Way ANOVA test, a $p < 0.05$ and a $levene > 0.05$ were obtained. The effectiveness test showed that 10% aloe vera extract had a more optimal effect on burn repair compared to 10% grape seed extract.

REFERENCES

- Abidin, Z., Kurdi, F., & Istiqomah, I. N. (2021). Efektivitas Pemberian Lidah Buaya Pada Pasien Luka Bakar Di Desa Yosowilangun Lumajang: The Effectiveness Of Giving Aloe Vera To Burn Patients In Yosowilangun Lumajang. *Jurnal Ilmiah Keperawatan (Scientific Journal Of Nursing)*, 7(1), 77–84.
- Agungpriyono, S., Prawira, A. Y., Darusman, H. S., Farida, W. R., & Novelina, S. (2020). Anatomi Makroskopis Dan Analisis Dinamika Profil Darah Pada Proses Penyembuhan Luka Pada Kulit Landak Jawa (*Hystrix Javanica*). *Jurnal Veteriner*, 21(1).
- Alepani, M., Wahyudi, J. T., & Tiranda, Y. (2022). Efektivitas Pemberian Aloevera Pada Proses Penyembuhan Luka Bakar: Literature Review. *Jkm: Jurnal Keperawatan Merdeka*, 2(1), 15–29.

Comparison of The Effectiveness of Grape Seed (*Vitis Vinifera*) With Aloe Vera (*Aloe Vera*) in The Repair of Burns in Wistar Rats Based on Wound Diameter

- Firdaus, N. Z., Alda, A. A., & Gunawan, I. S. (2020). Potensi Kandungan Biji Anggur Dalam Mempercepat Penyembuhan Luka. *Jurnal Penelitian Perawat Profesional*, 2(2), 139–146.
- Hasbi, M. R. R., & Waspodo, N. N. (2024). Efektivitas Pemberian Lidah Buaya (Aloe Vera) Terhadap Penyembuhan Luka Bakar. *Prepotif: Jurnal Kesehatan Masyarakat*, 8(1), 1081–1087.
- Hutauruk, U. R., Yu, F. J., Natali, O., & Nasution, S. W. (2022). Effectiveness Comparison Of Bandotan Leaves With Aloe Vera In Repair Of Burn Wound On Rats Based On Burn Wound Diameter. *Jambura Journal Of Health Sciences And Research*, 4(3), 656–667.
- Iga, T., Kato, K., & Karita, T. (2018). Subtrochanteric Fracture Of The Femur Accompanying Pre-Existing Ipsilateral Osteoarthritis Of The Hip Successfully Treated With Intramedullary Nailing In The Lateral Decubitus Position: A Case Report. *Cureus*, 10(7).
- Khairunnisa, K. A., Hazar, S., & Mulqie, L. (2022). Kajian Literatur Efek Farmakologi Biji Dan Buah Anggur (*Vitis Vinifera L.*). *Bandung Conference Series: Pharmacy*, 2(2), 762–772.
- Laguliga, J. A., Erviani, A. E., & Soekendarsi, E. (2021). Test The Potency Of *Jatropha Sap Jatropha Curcas Linn.* On The Speed Of Wound Healing Burns On Therats Skin *Rattus Norvegicus*.
- Lutfiah, A., Mellaratna, W. P., & Topik, M. M. (2023). Uji Efektivitas Ekstrak Lidah Buaya (Aloe Vera) Dalam Menghambat Pertumbuhan Bakteri *Propionibacterium Acnes* Secara In Vitro. *Jurnal Ilmiah Manusia Dan Kesehatan*, 6(2), 251–262.
- Martín Rubio, M. E., Grao Cruces, E., Millán-Linares, M. Del C., & Montserrat De La Paz, S. (2020). Grape (*Vitis Vinifera L.*) Seed Oil: A Functional Food From The Winemaking Industry. *Foods*, 9 (10), 1-20.
- Maternity, D. (2022). Efektivitas Penggunaan Lidah Buaya (Aloevera) Terhadap Penyembuhan Luka Perineum Pada Ibu Nifas Diwilayah Kerja Puskesmas Karang Anyar Lampung Selatan Tahun 2021. *Jurnal Ilmiah Bidan*, 6(2), 25–32.
- Naldaiz-Gastesi, N., Bahri, O. A., Lopez De Munain, A., Mccullagh, K. J. A., & Izeta, A. (2018). The Panniculus Carnosus Muscle: An Evolutionary Enigma At The Intersection Of Distinct Research Fields. *Journal Of Anatomy*, 233(3), 275–288.
- Ningsih, A. M. M., & Ambarwati, N. S. S. (2021). Pemanfaatan Lidah Buaya (Aloe Vera) Sebagai Bahan Baku Perawatan Kecantikan Kulit. *Jurnal Tata Rias*, 11(1), 91–100.
- Prasongko, E. T., Lailiyah, M., & Muzayyidin, W. (2020). Formulasi Dan Uji Efektivitas Gel Ekstrak Daun Kedondong (*Spondias Dulcis F.*) Terhadap Luka Bakar Pada Tikus Wistar (*Rattus Novergicus*). *Jurnal Wiyata: Penelitian Sains Dan Kesehatan*, 7(1), 27–36.
- Prastyoningsih, A., Wijayanti, W., Sari, A. P., Parwati, L., & Nurlita, R. A. (2024). Analisis Kualitatif Ekstrak Daging Lidah Buaya Dengan Metode Maserasi Etanol 96%. *Jurnal Kesehatan Kusuma Husada*, 27–34.
- Putra, I. M. A. S., & Erliana, N. K. E. (2022). Pengaruh Ekstrak Etanol Daun Pangi

- (Pangium Edule) Terhadap Penyembuhan Luka Bakar Pada Tikus Putih (Rattus Novergicus) Galur Wistar. *Jurnal Ilmiah Medicamento*, 8(2), 127–133.
- Septiawan, A. N., Emelda, E., & Husein, S. (2020). Aktivitas Antioksidan Kombinasi Ekstrak Etanol Lidah Buaya (Aloe Vera L.) Dan Ganggang Hijau (Ulva Lactuca L.). *Inpharmmed Journal (Indonesian Pharmacy And Natural Medicine Journal)*, 4(1), 11–24.
- Suriawanto, N. (2021). Pengaruh Pemberian Ekstrak Propolis Lebah Tanpa Sengat Pada Penyembuhan Luka Bakar Tikus Putih (Rattus Norvegicus). *Jurnal Bioteknologi Dan Biosains Indonesia*, 8(1), 68–76.
- Syafriana, V., Hamida, F., Puspita, D., Haryani, F., & Nanda, E. V. (2020). Aktivitas Antifungi Ekstrak Etanol Biji Anggur Terhadap *Malassezia Furfur* Dan *Trichophyton Mentagrophytes*. *Bioma*, 16(1), 21–30.
- Taype-Rondan, A., Tanaka, J. H. Z., & Merino-Garcia, N. (2017). Peruvian Scientific Production On Abortion In *Scopus*. *International Journal Of Preventive Medicine*, 8(1), 83.
- Wardani, H. K. (2020). *Wellness And Healthy*.
- Ananta, G. P. (2020). Potensi Batang Pisang (*Musa Pardisiaca L.*) Dalam Penyembuhan Luka Bakar. *Jurnal Ilmiah Kesehatan Sandi Husada*, 11(1), 334–340. <https://doi.org/10.35816/jiskh.v11i1.283>
- Aulia, R., Erviani, A. E., Tambaru, E., Hasanuddin, U., & Kemerdekaan, J. P. (2024). Volume 9, 9, 123–133.
- Firmansyah, D., & Setyaningsih, I. (2018). Formulasi Dan Uji Stabilitas Ekstrak Etanol Daun Lidah Buaya (*Aloe Vera L*) Konsentrasi 1% Dan 4%. *Medimuh*, 1(1), 7–16.
- Fuadi, A. (2021). *Tahta Media Group*.
- Hasanah, N., Purnama, F., Indah, S., Anggraeni, D., Ismaya, N. A., Kania, L., & Puji, R. (2020). [29] Hasanah, N., Indah, F. P., Anggraeni, D., Ismaya, N. A., & Puji, L. K. (2020). Perbandingan Formulasi Dan Uji Stabilitas Fisik Sediaan Gel Ekstrak Lidah Buaya (*Aloe Vera*) Dengan Perbedaan Konsentrasi. *Edu Masda Journal*, Vol 4 No 2 , 132-144. *Edu Masda Journal*, 4(2), 132–144. <http://openjournal.masda.ac.id/index.php/edumasda>
- Hasanah, M. G., Van Baar, M. E., Choudhry, M. A., Chung, K. K., Gibran, N. S., & Logsetty, S. (2020). Burn Injury. *Nature Reviews Disease Primers*, 6(1). <https://doi.org/10.1038/s41572-020-0145-5>
- Kadek, N., Dewi, A. S., Made, I., Adnyana, S., Putu, G., Sanjaya, H., Rusly, A. R., & Hamid, H. (2021). Epidemiologi Pasien Luka Bakar Di Rsup Sanglah Denpasar Tahun 2018-2019. *Intisari Sains Medis | Intisari Sains Medis*, 12(1), 219–223. <https://doi.org/10.15562/ism.v12i1.865>
- Natali, O. (2023). Perbandingan Efektivitas Daun Bandotan Dengan Lidah Buaya dalam Perbaikan Luka Sayat Pada Tikus Wistar. *Journal Majalah Kedokteran Andalas*, 46(1), 120–129. <http://jurnalmka.fk.unand.ac.id>
- Pardina, N. A., & Setyowatie, L. (2020). Tinjauan Literatur : Peran Astaxanthin Pada Luka Bakar. *Majalah Kesehatan*, 7(4), 273–284. <https://doi.org/10.21776/ub.majalahkesehatan.2020.007.04.7>
- Stress, O., St, D., Hiane, P. A., Pott, A., & C, K. De. (2023). *Metabolic Alterations. Comparison of The Effectiveness of Grape Seed (Vitis Vinifera) With Aloe Vera (Aloe Vera) in The Repair of Burns in Wistar Rats Based on Wound Diameter*

Sugiyono. (2020). Metodologi Penelitian Kuantitatif, Kualitatif Dan R & D.
Vii, S. N., & Pembelajarannya, B. D. A. N. (2022). Realisasi Strategis Pembelajaran
Biologi Berbasis Ict (Information And Comunnication Technology)
Dengan Penerapan Kerangka Kerja Berbasis Keterampilan Abad 21.