

CASE REPORT ; MANAGEMENT OF CHRONIC PERIODONTITIS AFTER 2 MONTHS OF TRAFFIC ACCIDENTS

Heru Maksmara

Periodonsia Dept. RSPAU Dr S Hardjolukityo Diskesau, Yogyakarta, Indonesia

Email: maxmaraheru@gmail.com

ARTICLE INFO ABSTRACT

Received:
Ferbruary, 26th 2022

Revised:
March, 15th 2022

Approved:
March, 16th 2022

The availability of domestic raw materials is gradually decreasing, while the need for energy sources is increasing. Therefore, it is necessary to have the availability of renewable energy sources, one of which is biomass. In this study, researchers will discuss the waste of sugarcane bagasse and orange peel which can be used as briquettes. Usually, these wastes are only used as animal feed, sometimes they are just thrown away. The goals and benefits expected by the author in this study are, to provide information that the manufacture of briquettes from bagasse and Pacitan orange peel can be used as an alternative fuel. So, it can be implemented to reduce fossil fuels, whose availability is getting less and less. In the study, the best results were on the adhesive variable 20% ratio 1:2 with a calorific value of 5,949,114 cal/gram, 9% moisture content, 9% ash content.

KEYWORDS

Bagasse, Briquettes, Energy, Orange Peel



This work is licensed under a Creative Commons Attribution-ShareAlike 4.0 International

INTRODUCTION

Reconstruction of bone damage of teeth has been done for many years with varying degrees of success (Feuillet, Keller, & Agossa, 2018). If the procedure is done with a full understanding of the applicable biological principles and if the proper clinical techniques are used, it can be very successful (Davis et al., 2020).

Heru Maksmara. (2022). Case Report; Management of Chronic Periodontitis After 2 Months of Traffic Accidents. Journal Eduvest.
How to cite: Vol 2(3): 498-504
E-ISSN: 2775-3727
Published by: <https://greenpublisher.id/>

Most of orofacial trauma involving teeth and supporting tissue structure that is a true dental emergency, though, the absence of teeth having a healthy support network to return to normal after trauma (Eden, Onetto, & O'Connell, 2021). Rational therapy can be taken to overcome this problem, starting from accurate diagnosis and assess signs and symptoms occur, multiple traumas are very difficult to overcome. Intraoral examination, checking for bleeding and swelling are also mucosal tissue and gingival lacerations, when it is covered with blood clots and suction clean with tampons alone (Hogrefe, 2020). Abnormality such as tooth shape regardless of the socket, fracture crack too. Shakiness of teeth horizontally and vertically by moving the fingers slowly assessed course, percussion and pressure checks are very hurt (Natterson-Horowitz & Bowers, 2020).

Orofacial trauma causes great damage to the tissue structures supporting the teeth (Pigg et al., 2021). To repair the damage/loss of tissue structures supporting the teeth, we can do the restoration/remodeling tissue structures supporting the teeth (Hernández-Monjaraz, Santiago-Osorio, Monroy-García, Ledesma-Martínez, & Mendoza-Núñez, 2018). Reconstruction of the bone teeth support is an action seeking return of biomedical with the patient's teeth still remain in place, with some improvement in the structure of the tooth supporting tissue (Yu et al., 2021). Reconstruction of these teeth may include one or several teeth, in order to maintain masticatory function, comfort, and or aesthetic (Duong et al., 2022). Transplantation is a tissue graft, required for the correction of anatomic surgical repair during fracture and osteotomy, without interrupting vascularization as well as the fixation stability of the bone construction (Dalisson et al., 2021).

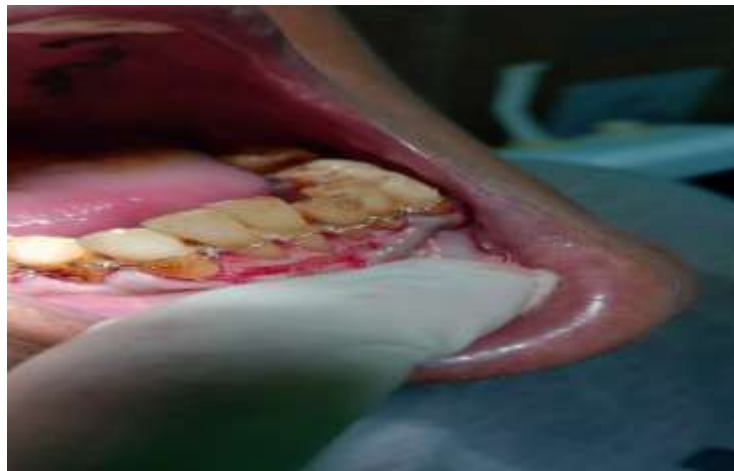Bone is a dynamic tissue that undergoes a process of continuous remodeling in stable condition and there is a balance between the processes of bone resorption and deposition (Sykes, Bradfield, & Naidu, 2021). Remodeling process begins with the activation phase which is described by the displacement of osteoclast precursors into the bone area that will resorb and the occurrence of cell attachment and fusion of osteoclast precursor cells into multinucleated osteoclasts (Jann, Gascon, Roux, & Faucheux, 2020). The second phase is the phase of resorption, bone by osteoclasts resorption possibly helped by the existence of mononuclear phagocytes to the resorption area (Sivaraj et al., 2022). The opposite happens next stage in which cells resembling mononuclear phagocytes resorption modify the surface and form a morphological structure, identified as a cement line (Lerner, Kindstedt, & Lundberg, 2019). This phase is followed by phase formation where osteoblasts differentiate on the side and start resorption on steoid and deposition in bone (Isojima & Sims, 2021). The end of this phase is characterized by a resting phase, the absence of osteoid is left between the lining cells and bone which mineralized.

Hydroxyapatite polyurethane sponge is a alloplast - bone graft material that has the ability and osteoconduction and osteoinduction (Bajuri, Selvanathan, Dzeidee Schaff, Abdul Suki, & Ng, 2021). Presence of bone morphogenic proteins (BMPs) to bone graft material will alter the cells - the cells into osteoblasts around, helping mesenchymal cell migration, adhesion and osteogenesis in intraboni damage. In the histological study of this material showed the regeneration of cementum, periodontal ligament and alveolar bone, in humans the presence of new attachment apparatus. Clinical studies have also demonstrated an increase in probing depth and significant clinical attachment level.

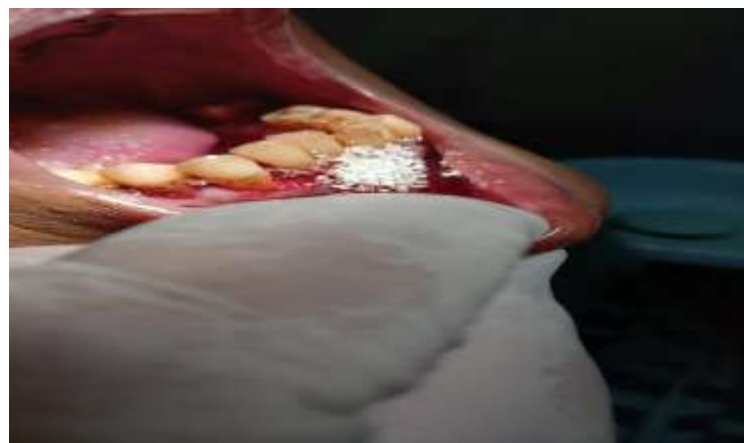Case report

60 years old male patient, heavy smoker, hypertension sufferer, had a traffic accident 2 months ago. On intra-oral examination, poor oral hygiene was found, tooth loss was 11,12,13, there was 3rd degree tooth mobility in teeth 21,22. General tooth mobility is present in the mandibular teeth, inflammation is present, and the patient has difficulty chewing food.

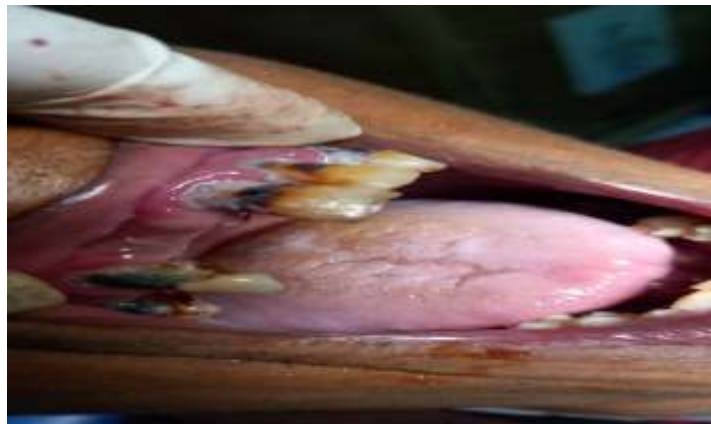Diagnose ; Cases of chronic periodontitis stage IV grade C, is a condition of periodontal disease caused by gram negative bacteria for a long time, which results in alveolar bone destruction >5 mm and affecting >5 teeth. Usually, acquired due to trauma, there is a fractured bone defect, and 20 remaining teeth are in the mouth, the condition is exacerbated if the patient has systemic disease, poor oral hygiene, and is a heavy smoker.



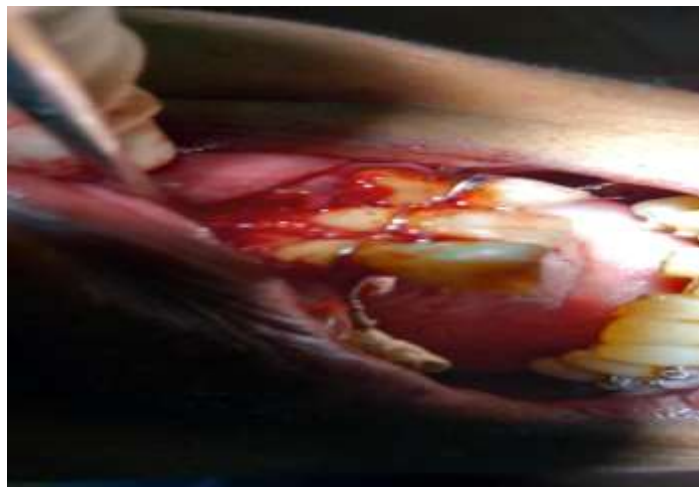
Picture 1. Flap gingiva lower jaw and wire splint



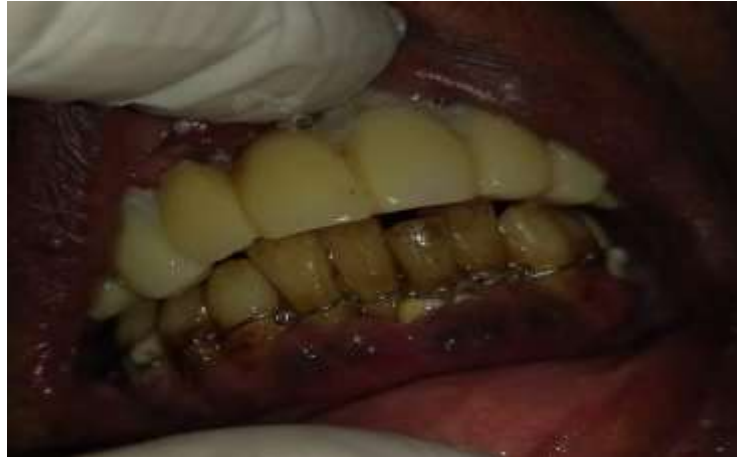Picture 2. Bone graft



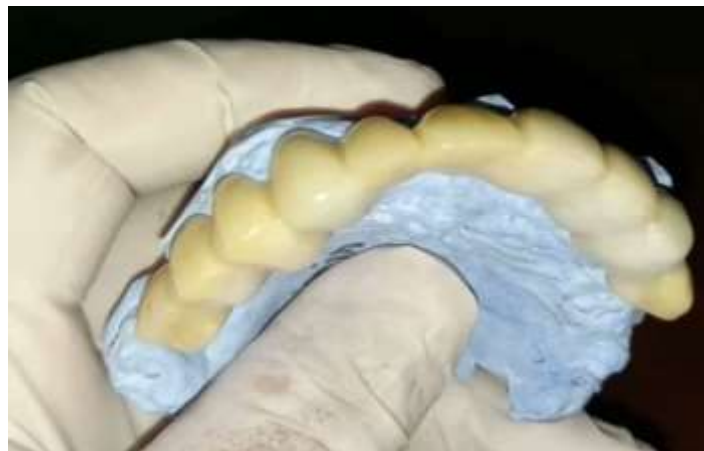Picture 3. Bad oral hygiene



Picture 4. Flag gingiva upper jaw



Picture 5. Acrylic fix bridge



Picture 6. 3 months after surgery

management

Reconstruction fractured tooth after root canal treatment is done by installing pin, as well as smoothing the root surfaces of teeth with composite. Clean the area of operation with a solution of 3% peroxide. Enter hydroxyapatite polyurethane sponge - alloplast bone graft material to the brim on the socket, reconstruction of the bone and teeth. Fit splinting on tooth implant and its neighbors, fixasi must be strong to fight the force of gravity so that may change as airline pilots do. Note the dental occlusion and articulation time of implantation. Splinting using wires 0.4 mm. Tailoring gingiva toward the teeth crown bridge should also be considered. Install the pack on the area of periodontal surgery well, it will remain attached to 10 days.

The patient is given antibiotics metronidazole 500 mg 2x a day for 3 days, clindamycin 300 mg 2x a day for 6 days, the rapid reaction of sodium diclofenac 50 mg three times daily until 6 days, mefenamic acid 500 mg 2 times daily until 6 days. Day 10th periodontal pack is released, as well as sewing thread.

RESULT

3 months post-surgery, there is no bleeding on probing, probing depth of 3 mm, percussion and pressure wasn't pain, no tooth mobility. The labial gingival recession had 2 mm. Patients are advised to do a re-entry operations.

6th months to do re-entry operations, with the addition of bone graft material, in order to get a good bone density. Gingival recession, gingival grafts can be done to improve the contour. Drugs and the same advice given to the patient.

REFERENCES

- Bajuri, Mohd Yazid, Selvanathan, Nanchappan, Dzeidee Schaff, Fatin Nadira, Abdul Suki, Muhammad Haziq, & Ng, Angela Min Hwei. (2021). Tissue-engineered hydroxyapatite bone scaffold impregnated with osteoprogenitor cells promotes bone regeneration in sheep model. *Tissue Engineering and Regenerative Medicine*, 18(3), 377–385.
- Dalisson, Benjamin, Charbonnier, Baptiste, Aoude, Ahmed, Gilardino, Mirko, Harvey, Edward, Makhoul, Nicholas, & Barralet, Jake. (2021). Skeletal regeneration for segmental bone loss: Vascularised grafts, analogues and surrogates. *Acta Biomaterialia*, 136, 37–55.
- Davis, Karen D., Aghaeepour, Nima, Ahn, Andrew H., Angst, Martin S., Borsook, David, Brenton, Ashley, Burczynski, Michael E., Crean, Christopher, Edwards, Robert, & Gaudilliere, Brice. (2020). Discovery and validation of biomarkers to aid the development of safe and effective pain therapeutics: challenges and opportunities. *Nature Reviews Neurology*, 16(7), 381–400.
- Duong, Ho-Yan, Rocuzzo, Andrea, Stähli, Alexandra, Salvi, Giovanni E., Lang, Niklaus P., & Sculean, Anton. (2022). Oral health-related quality of life of patients rehabilitated with fixed and removable implant-supported dental prostheses. *Periodontology 2000*, 88(1), 201–237.

- Eden, Ece, Onetto, Juan Eduardo, & O'Connell, Anne C. (2021). Extension of a novel diagnostic index to include soft tissue injuries: Modified Eden Baysal Dental Trauma Index. *Dental Traumatology*, 37(6), 749–757.
- Feuillet, Damien, Keller, Jean François, & Agossa, Kevimy. (2018). Interproximal Tunneling with a Customized Connective Tissue Graft: A Microsurgical Technique for Interdental Papilla Reconstruction. *International Journal of Periodontics & Restorative Dentistry*, 38(6).
- Hernández-Monjaraz, Beatriz, Santiago-Osorio, Edelmiro, Monroy-García, Alberto, Ledesma-Martínez, Edgar, & Mendoza-Núñez, Víctor Manuel. (2018). Mesenchymal stem cells of dental origin for inducing tissue regeneration in periodontitis: a mini-review. *International Journal of Molecular Sciences*, 19(4), 944.
- Hogrefe, Christopher. (2020). Facial Trauma. In *Sports-related Fractures, Dislocations and Trauma* (pp. 753–802). Springer.
- Isojima, Tsuyoshi, & Sims, Natalie A. (2021). Cortical bone development, maintenance and porosity: genetic alterations in humans and mice influencing chondrocytes, osteoclasts, osteoblasts and osteocytes. *Cellular and Molecular Life Sciences*, 78(15), 5755–5773.
- Jann, Jessica, Gascon, Suzanne, Roux, Sophie, & Faucheux, Nathalie. (2020). Influence of the TGF- β superfamily on osteoclasts/osteoblasts balance in physiological and pathological bone conditions. *International Journal of Molecular Sciences*, 21(20), 7597.
- Lerner, Ulf H., Kindstedt, Elin, & Lundberg, Pernilla. (2019). The critical interplay between bone resorbing and bone forming cells. *Journal of Clinical Periodontology*, 46, 33–51.
- Natterson-Horowitz, Barbara, & Bowers, Kathryn. (2020). *Wildhood: the astounding connections between human and animal adolescents*. Scribner.
- Pigg, Maria, Nixdorf, Donald R., Law, Alan S., Renton, Tara, Sharav, Yair, Baad-Hansen, Lene, & List, Thomas. (2021). New international classification of orofacial pain: what is in it for endodontists? *Journal of Endodontics*, 47(3), 345–357.
- Sivaraj, Kishor K., Majev, Paul Georg, Jeong, Hyun Woo, Dharmalingam, Backialakshmi, Zeuschner, Dagmar, Schröder, Silke, Bixel, M. Gabriele, Timmen, Melanie, Stange, Richard, & Adams, Ralf H. (2022). Mesenchymal stromal cell-derived septoclasts resorb cartilage during developmental ossification and fracture healing. *Nature Communications*, 13(1), 1–16.
- Sykes, L. M., Bradfield, Charles, & Naidu, Karmisha. (2021). Alveolar bone resorption following tooth extraction characteristically illustrated. *South African Dental Journal*, 76(9), 545–549.
- Yu, Peng, Yu, Fanyuan, Xiang, Jie, Zhou, Kai, Zhou, Ling, Zhang, Zhengmin, Rong, Xiao, Ding, Zichuan, Wu, Jiayi, & Li, Wudi. (2021). Mechanistically Scoping Cell-free and Cell-dependent Artificial Scaffolds in Rebuilding Skeletal and Dental Hard Tissues. *Advanced Materials*, 2107922.