

VERTIGO AS INITIAL SYMPTOM OF CEREBELLAR HEMORRHAGE IN ADULT WOMAN : A CASE REPORT

Dessy Gita Hepsari¹, Novian Wibowo²
^{1,2} Baptis Hospital, Kediri, Indonesia
Email: dessygitaa@gmail.com

ABSTRACT

Vertigo, difficulty walking, and loss of balance/coordination are among the symptoms of stroke in 50% of stroke cases. Vertigo due to cerebrovascular disease is generally associated with other neurological signs such as cranial nerve abnormalities, hemiparesis, facial weakness, diplopia, hyperesthesia, and Horner's syndrome. A 42-year-old woman came to the emergency department with complaints of dizziness, nausea, and frequent vomiting for the previous 4 hours. The symptoms are also accompanied by a feeling of tingling on the left side of the face, and the left eyelid cannot open optimally. The patient has a history of uncontrolled hypertension. The HINTS test revealed central vertigo, and the patient also found dysdiadochokinesis, ataxia, and dysmetria. A non-contrast head CT scan showed ICH in the left cerebellum with a volume of 6.9 cc. Based on the results of these examinations, the patient was diagnosed with cerebellar hemorrhage. The blood supply to the brainstem, cerebellum, and inner ear comes from the vertebrobasilar vascular system. Blockage or rupture of blood vessels in one of the main branches of this system can cause symptoms of vertigo. Symptoms of vertebrobasilar stroke vary widely and depend on which of the three main circumferential branches is affected; posterior inferior cerebellar artery, anterior inferior cerebellar artery, or superior cerebellar artery. Vertigo in patients who have risk factors for stroke accompanied by other neurological symptoms should be considered for a thorough neurological examination to evaluate the possibility of cerebrovascular disease.

KEYWORDS *Vertigo, Cerebrovascular Disease, Cerebellar Hemorrhage.*



This work is licensed under a Creative Commons Attribution-ShareAlike 4.0 International

INTRODUCTION

Vertigo is a sensation like wrong movement in oneself or the surrounding area. This perception often feels like a spinning or swaying movement (Shaikh & Manto, 2019). Vertigo is not a disease, but rather a symptom of various diseases with different etiologies. Among them is dysfunction of the vestibular system, both

How to cite: Dessy Gita Hepsari, Novian Wibowo(2024). Vertigo as Initial Symptom of Cerebellar Hemorrhage in Adult Woman : A Case Report. *Journal Eduvest*. 4(7): 5876-5891
E-ISSN: 2775-3727
Published by: <https://greenpublisher.id/>

peripheral (inner ear, vestibular nerve) and central (brain stem, cerebellum) (Strupp et al., 2020).

Vertigo, difficulty walking, loss of balance/coordination are among the symptoms of stroke in 50% of stroke cases. Vertigo due to cerebrovascular disease (CVD) is generally associated with other neurological signs. Sometimes cerebellar and brain stem strokes can appear with prominent symptoms of vertigo and resemble acute vestibulopathy, which can cause delays in stroke diagnosis (Chakor & Eklare, 2012). Luckily, there are various clues in the physical examination that can distinguish between the causes of acute vertigo/dizziness resulting from a central or peripheral disorder. If there are additional neurological symptoms such as cranial nerve abnormalities, hemiparesis, facial weakness, diplopia, hyperesthesia, and Horner's syndrome, then central vertigo must immediately be suspected as the main cause (Armato et al., 2014). Cerebellar hemorrhage represents approximately 10% of all cerebellar strokes. Correct identification of cerebellar stroke is important to determine appropriate management and improve the prognosis of the disease, especially during the acute phase (Choi et al., 2013).

RESEARCH METHOD

Case Report

A 42-year-old woman came to the emergency department with complaints of dizziness, nausea and frequent vomiting for the previous 4 hours. The symptoms are also accompanied by a feeling of tingling on the left side of the face and the left eyelid cannot open optimally. There is no weakness in the upper extremities and lower extremities, the patient has difficulty standing. The patient denies hearing loss, fever, seizures, or other complaints. The patient has history of uncontrolled hypertension for the last 3 years and does not take regular medication. The vital signs showed blood pressure 200/100, pulse 94 times per minute, breathing 20 times per minute, temperature 36°C, and GCS 14. On physical examination, a head impulse test was carried out, the results were normal, bidirectional nystagmus, and the test of skew was positive, whose suggests to central vertigo. The patient also found dysdiadochokinesis, ataxia, and dysmethria. Motoric and sensory examination of all four extremities were normal.

On examination with a non-contrast head CT scan, the results showed suspect ICH in the left cerebellum with a volume of 6.9 cc (Figure 1 & Figure 2). In supporting examinations, abnormal results were obtained for potassium of 2.72. Based on the results of these examinations, the patient was diagnosed with cerebellar hemorrhage with hypertension and hypokalemia. The patient was given mannitol therapy 125 ml every 6 hours for 3 days, betahistine 6 mg every 12 hours, amlodipine 10 mg every 24 hours, lisinopril 10 mg every 24 hours, dopamet 250 mg every 8 hours, and nicardipine drip according to the protocol. The patient was also given 2 flasks or 50 ml of 7.46% Kcl fluid mixed in 500 ml of 0.9% NS infusion given within 24 hours to treat hypokalemia. After 5 days of treatment at the hospital, the patient was able to go home from the hospital with reduced dizziness, reduced tingling on the left side of the face, the left eyelid could open and close well, and blood pressure was below 140/80.

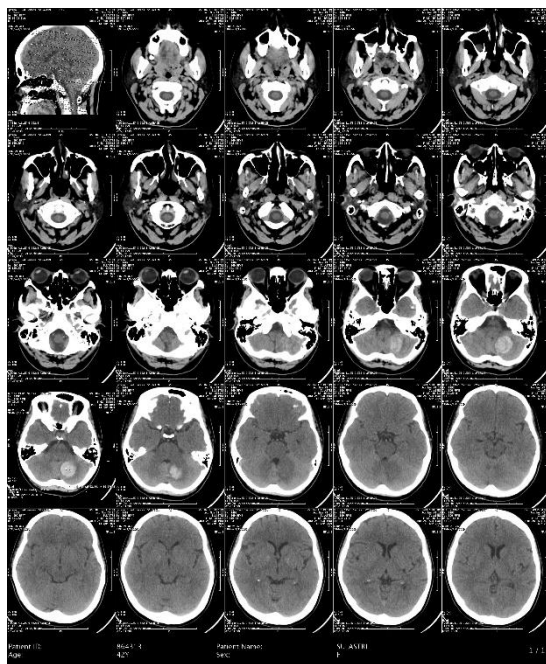


Figure 1. non-contrast head CT scan showed ICH in the left cerebellum

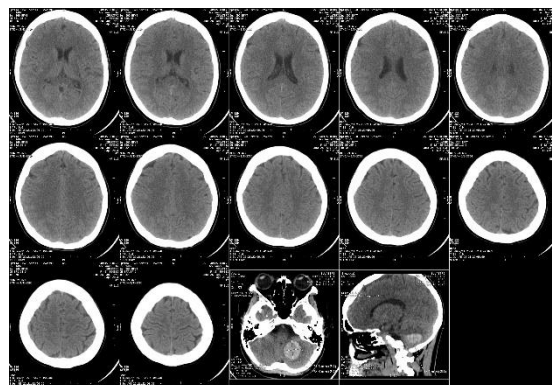


Figure 2. non-contrast head CT scan showed ICH in the left cerebellum with with a volume of 6.9 cc

RESULTS AND DISCUSSION

Patients with vascular vertigo usually present with acute vestibular syndrome (AVS), which refers to the onset of acute symptoms of vertigo or dizziness accompanied by nausea or vomiting, head movement intolerance, and instability of body balance (Kim et al., 2022). The presence of these symptoms should lead to a thorough neurological examination and evaluation of possible cerebrovascular disease in patients with risk factors for stroke.

HINTS examination (head-impulse, nystagmus, test of skew) helps differentiate possible stroke (central cause) from acute vestibular syndrome (peripheral cause) (Hsu et al., 2016). The first examination is horizontal head impulse. The presence of refixation saccadic movements was defined as a positive result. If the results are normal, then the vertigo is central type. The head impulse test has a sensitivity of 11.1% and a specificity of 100% in differentiating central vestibular disorder from vestibular migraine. The next examination is a nystagmus examination. The results are said to be positive if the patient complains of dizziness and has nystagmus. On examination of nystagmus, if it is caused by central vertigo, then the direction of the nystagmus is horizontal, pure torsional or pure vertical, there is a change in direction, it can change direction with convergence, it can change direction or intensity with changes in head or eye position. Next is the test

of skew; the presence of vertical misalignment in the eyes indicates the presence of central vertigo. Apart from that, other tests can also be carried out, such as the Romberg test. The Romberg test is said to be positive if the patient can maintain his balance with his eyes open. When this test is performed and the patient falls to one side with either eyes open or closed, the abnormality can be confirmed to be in the cerebellum. If the symptoms are more suggestive of central vertigo, a neurological examination needs to be carried out (Pricilia & Kurniawan, 2021). Vertigo due to CVD, is associated with fewer vegetative symptoms and more severe imbalance and associated brainstem signs.

The blood supply to the brainstem, cerebellum, and inner ear comes from the vertebrobasilar vascular system. Blockage of one of the main branches of this system can cause symptoms of vertigo. Symptoms of vertebrobasilar ischemic stroke (VIS) vary widely and depend on which of the three main circumferential branches is blocked; posterior inferior cerebellar artery, anterior inferior cerebellar artery, or superior cerebellar artery (Thompson & Amedee, 2009).

Occlusion of the posterior inferior cerebellar artery will cause lateral medullary infarction and result in lateral medullary syndrome, also known as Wallenberg's syndrome. Manifestations of the condition include vertigo, nystagmus, balance disorders, ipsilateral limb ataxia and facial pain or numbness, contralateral body hemianesthesia, Horner's syndrome, dysphagia, hoarseness, and rarely, facial nerve paralysis. Lateral pontomedullary infarction due to occlusion of the anterior inferior cerebellar artery will cause lateral inferior pontine syndrome. This syndrome is characterized by symptoms similar to Wallenberg's syndrome with striking differences. Involvement of cranial nerves VII and VIII causes ipsilateral facial paralysis, tinnitus, and hearing loss, respectively. However, dysphagia and hoarseness are not seen because cranial nerve nuclei IX and X are not involved with anterior inferior cerebellar artery occlusion. Lateral superior pontine syndrome occurs when the superior cerebellar artery is blocked. With this syndrome, a person can experience vertigo, nystagmus, balance disorders, ataxia of the ipsilateral extremities and facial pain or numbness, contralateral body hemianesthesia, and Horner's syndrome. What differentiates this syndrome is the finding of contralateral vibration and temperature disorders due to involvement of the medial lemniscus.

Cerebellar hemorrhage occurs in approximately 10% of all intracranial hemorrhages with a low annual incidence of 1% to 2% of all strokes. Cerebellar hemorrhage can occur spontaneously, due to stroke or as a result of trauma, and most often occurs in middle-aged and elderly adults. Patients usually have underlying risk factors that cause bleeding such as hypertension or small vessel disease (Muthmainnina & Kurniawan, 2022). In massive cerebellar hemorrhage, the condition can deteriorate quickly to coma and even death. Small cerebellar hemorrhages, especially around the vermis, sometimes cause symptoms of dizziness with nystagmus determined by changes in position similar to BPPV conditions.(3) Clinical manifestations of cerebellar hematoma appear suddenly, such as attacks of severe vertigo, ataxia without weakness, and signs of increased intracranial pressure such as headache, vomiting, and decreased consciousness (Lalla et al., 2012).

Computerized tomography (CT) imaging of the head without contrast is a rapid and widely available examination, making it the first and most efficient evaluation method for patients who present with signs and symptoms of possible cerebellar hemorrhage. Most surgeons recommend that the hematoma be surgically removed as soon as possible if the diameter of the hematoma is more than 40 mm or the volume is more than 15 ml and there is a compression in the brainstem or hydrocephalus. In contrast, patients who have a GCS score of 14 or more, a small hematoma (less than 40 mm), and no evidence of hydrocephalus can be treated conservatively (Wu et al., 2010).

CONCLUSION

Vertigo can be an early symptom of dysfunction of the vestibular system, both peripheral and central. Patients with suspected vertigo due to cerebrovascular disease, in this case cerebellar hemorrhage, an appropriate physical examination is needed to support the presence of central vertigo, and it is also necessary to pay attention to the presence of visible neurological signs. Early detection of the disease and appropriate treatment are necessary to prevent further brain damage, disability and even death.

REFERENCES

- Armato, E., Ferri, E., Pinzani, A., & Ulmer, E. (2014). Cerebellar haemorrhage mimicking acute peripheral vestibulopathy: the role of the video head impulse test in differential diagnosis. *Acta Otorhinolaryngologica Italica*, 34(4), 288.
- Chakor, R. T., & Eklare, N. (2012). Vertigo in cerebrovascular diseases. *Int J Otorhinolaryngol Clin*, 4(1), 46–53.
- Choi, K.-D., Lee, H., & Kim, J.-S. (2013). Vertigo in brainstem and cerebellar strokes. *Current Opinion in Neurology*, 26(1), 90–95.
- Hsu, Y.-H., Hu, H.-Y., Chiu, Y.-C., Lee, F.-P., & Huang, H.-M. (2016). Association of sudden sensorineural hearing loss with vertebrobasilar insufficiency. *JAMA Otolaryngology–Head & Neck Surgery*, 142(7), 672–675.
- Kim, J.-S., Newman-Toker, D. E., Kerber, K. A., Jahn, K., Bertholon, P., Waterston, J., Lee, H., Bisdorff, A., & Strupp, M. (2022). Vascular vertigo and dizziness: Diagnostic criteria. *Journal of Vestibular Research*, 32(3), 205–222.
- Lalla, R., Malhotra, H. S., Garg, R. K., & Verma, R. (2012). Conservative management in a rare case of spontaneous bilateral cerebellar haemorrhage. *Case Reports*, 2012, bcr2012006177.
- Muthmainnina, A. N., & Kurniawan, S. N. (2022). Tension Type Headache (TTH). *Journal of Pain, Headache and Vertigo*, 3(2), 41–44.
- Pricilia, S., & Kurniawan, S. N. (2021). Central vertigo. *Journal of Pain, Headache and Vertigo*, 2(2), 38–43.
- Shaikh, A. G., & Manto, M. (2019). Vertigo in Cerebellar Disease—Do the Eyes Have It or Is There More to Perceive? In *The Cerebellum* (Vol. 18, pp. 295–297). Springer.
- Strupp, M., Długaiczek, J., Ertl-Wagner, B. B., Rujescu, D., Westhofen, M., & Dieterich, M. (2020). Vestibular disorders: diagnosis, new classification and

- treatment. *Deutsches Ärzteblatt International*, 117(17), 300.
- Thompson, T. L., & Amedee, R. (2009). Vertigo: a review of common peripheral and central vestibular disorders. *Ochsner Journal*, 9(1), 20–26.
- Wu, Y.-T., Hsieh, M.-F., Chu, H.-Y., Lu, S.-C., Chang, S.-T., & Li, T.-Y. (2010). Recurrent cerebellar hemorrhage: case report and review of the literature. *The Cerebellum*, 9, 259–263.