
LATE ONSET ACQUIRED PROTHROMBIN COMPLEX DEFICIENCY (APCD) IN A 27 DAYS OLD INFANT: A RARE CASE REPORT

Farahdina Farahdina, Ima Sri Wahyuni, Vatine Adila

Brawijaya University

E-mail: farahdina95@gmail.com, imasw34@gmail.com, vatineadila@gmail.com

ARTICLE INFO ABSTRACT

Received:
August, 26th 2021
Revised:
**September, 14th
2021**
Approved:
**September, 16th
2021**

Acquired prothrombin complex deficiency (APCD) is a disease that occurs due to a deficiency in the coagulation factors that make up the prothrombin complex (II, VII, IX, and X), which are highly dependent on the presence of vitamin K in carrying out their functions. This study uses a qualitative method with the type of case report. The sampling technique used in this study the author uses the Random Sampling technique or by using the Slovin formula in Husein Umar. Where each population has the same opportunity to be selected as a sample in this study. Based on the analysis and discussion, it can be concluded that APCD is a disease with a high mortality rate, and those who survive are also threatened with disability for the rest of their lives. So that early detection and holistic treatment need to be done to prevent death and disability.

KEYWORDS

APCD, Infant, 27 Days Old



**This work is licensed under a Creative Commons
Attribution-ShareAlike 4.0 International**

INTRODUCTION

Acquired prothrombin complex deficiency (APCD) is a disease that occurs due to a deficiency in the coagulation factors that make up the prothrombin complex (II, VII, IX, and X), which are highly dependent on the presence of vitamin K in carrying out their functions (Pantiyasa, 2011). Some studies suggest that this disorder is caused by vitamin

Farahdina Farahdina, Ima Sri Wahyuni, Vatine Adila. (2021) Late Onset Acquired Prothrombin Complex Deficiency (APCD) in a 27 Days Old Infant: a Rare Case Report. Journal Eduvest. 1(9): 982-987

How to cite:

E-ISSN: 2775-3727

Published by: <https://greenpublisher.co.id/>

K deficiency in infancy, but vitamin K supplementation alone cannot solve the problem (Bhanchet et al., 1977).

Global findings regarding this disease vary widely. Due to the lack of understanding of the underlying etiology, prevention in high-risk groups is difficult to provide. Published epidemiological studies were conducted in Thailand, with an incidence of 35.5 per 100,000 live births (Unghusak, Tishyadhigama, Choprapawon, Sawadiwutiping, & Varintarawat, 1988) with a mortality rate of 35%, indicating a fairly large number as a cause of infant mortality (Bhanchet-Israngkura & Kashemsant, 1975).

Most cases that are brought to the hospital are caused by spontaneous bleeding that occurs in the early stages of life, which is less than three months of age (Koojaroenprasit, 2012). It is very rare for the parents to check neonates' complaints at the earliest possible condition which results in the treatment given to the patient being a little late and worsening the patient's prognosis (Gunawan & YOESTINI, 2011).

This case report will report the incidence of late onset APCD to increase awareness when there are early symptoms that appear in patients even though the symptoms seem vague. So that treatment can be given as early as possible before more massive bleeding occurs (Bruck, 1992) (Fristadi & Bharata, 2015) (Scholes, 1998).

A 27-days-old neonatus looked hypoactive was taken by his parents to the hospital because decreased of consciousness, and his body was bluish since 1 hour ago after drinking milk. Alloanamnesis from the parents found that the patient often turned blue and was not breathing suddenly. Then after being awakened, the patient breathes again. No previous history of vomiting and seizures. There is no history of fever, bowel disorders and the urination within normal limits. The history of pregnancy and delivery was a normal delivery at hospital with 35 weeks of preterm pregnancy and was assisted by a midwife. There is no history of taking drugs during pregnancy such as excessive antibiotics, anticonvulsants, anti-tuberculosis drugs, or anticoagulants. After delivery, the baby was quite good, there was no history of jaundice, head trauma, or previous excessive swinging. The patient was given breast milk and sometimes given formula milk. The history of postnatal vitamin K injection is unknown.

Physical examination showed the baby looked pale and somnolent with the Children Coma Scale (CSS) 7 (E1M4V2). Examination of vital signs showed the pulse rate was 158 beats / minute (sufficient, strong, and regular filling), an irregular breath rate of 10 times / minute, and the body temperature was 36.8 ° C. The neonatal weight was 2.5 kilograms and the birth weight now was 2.6 kilograms. The baby's head looks normal, with isochore pupils 3mm and 3mm, and the mouth looks bluish with the suction and swallow reflex was weak. Neurological examination shows there is no spasticity in the extremities. Physical examination of the chest and abdomen within normal limits. There was no gastrointestinal bleeding from the orogastric tube. There is a bluish appearance on the skin and there is no wound on the skin and the turgor returns normal.

Hematology laboratory profile shows normal conditions (hemoglobin level 15.6 g/dL, hematocrit 44.2%, MCV 95.3 fl, MCH 33.6 pg, MCHC 35.3 g/dL), with leukopenia (leukocytes 4.1x1000 /uL) but there is a thrombocytopenia (70,000 cells / mm³), with blood glucose (102 mg/dL) and electrolytes (Sodium 133 mmol/L, Potassium 4.7 mmol/L, and Chloride 98 mmol/L) within normal limits and a slight increase in calcium at a lab value of 10.3 mg/dL.

Blood gas analysis showed a respiratory alkalosis with a pH of 7.59 pCO₂ 18 mmHg, 141 mmHg pO₂ dg base excess -2.2 mmol/L, hco₃⁻ 17.3 mmol/L.

On the hemostatic status examination, it was found that normal prothrombin time (PT) (13 seconds) but the activated partial thromboplastin time (aPTT) was extended by

63 seconds. Head ultrasound imaging shows there is a bleeding on appointed from the picture below.

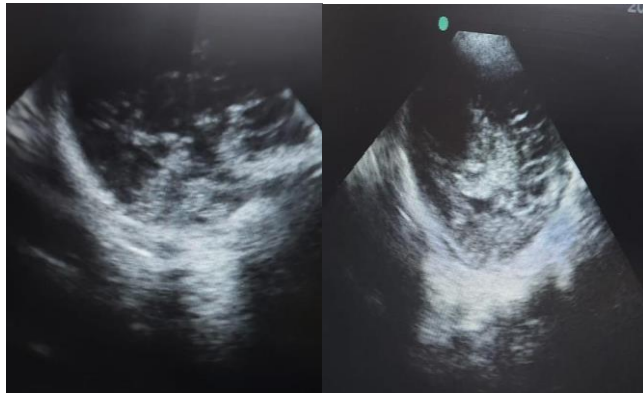


Figure 1. Ultrasound examination of the head

The patient was diagnosed with low onset of Acquired prothrombin complex deficiency condition and was given therapy according to the protocol. The patient was treated with intubation procedure. The patient was infused using Dextrose-10 / Normal Saline (1/5) with 290 mL / 24 hours. Infusion of NS 0.9% 30cc / kg. PRC transfusion 30cc / 2tpm, ranitidine 2x3 mg, ampiculbactam 2x150mg, phenytoin 60mg if seizures (+) midazolam inj 0.1-0.4 mg / kg / hour. 2x3 mg furosemide injection. Pro furosemide 1.5 mg post cg 0.2 cc. The patient also was given 3meqdrip natrium bicarbonate correction, dobutamine 5meq / kg / hr, miloz 0.1-0.4mg / kg / hr. The patient was observed in the neonatal room and a CT scan is planned if the patient has been stable condition.

RESEARCH METHOD

This study uses a qualitative method with the type of case report. The sampling technique used in this study the author uses the Random Sampling technique or by using the Slovin formula in Husein Umar. Where each population has the same opportunity to be selected as a sample in this study.

RESULT AND DISCUSSION

The case that we present is a 27-day-old baby with drowsiness and decreased consciousness. Initial suspicion needs to be explored, especially the patient's body and lips become bluish in color and occasionally do not breathe. The age of our patient is still the age at risk of the first onset of APCD, considering that some studies have an average age of onset of 40 days although it can be longer than that up to three months. Most of the complaints of APCD patients when they first come to the hospital are seizures, coma, drowsiness, or the presence of focal neurological abnormalities. These symptoms arise due to the process of abnormalities that occur in the intracranial so that it can cause an increase in intracranial pressure and affect consciousness and breathing (Wahab, 2020) (Bhanchet-Israngkura & Kashemsant, 1975).

Our patients have been breastfed since birth and occasionally get formula milk. A study showed that babies who only consumed breastmilk had a higher risk of developing APCD compared to babies who were alternated with formula or formula alone. Although breastmilk has complete nutrition, vitamin K is not able to penetrate the breastmilk

barrier so it is found in breast milk at low concentrations (Gretz & Basuroy, 2013). In infants who do not have abnormalities in their coagulation conditions, consumption of breast milk alone is sufficient to meet daily vitamin K needs, but in infants with APCD, additional vitamin K is necessary. In addition, there are doubts about the history of post-partum intramuscular vitamin K administration, so that it can increase the suspicion of vitamin K deficiency in patients.

On physical examination, our patient found somnolence of consciousness with some bluish spots. In some areas of the skin appear bruising that is bluish in color. This color can be one of the manifestations of APCD on the skin, the emergence of purpura which can be an early sign of APCD symptoms. Although often overlooked, purpura is an early sign before the appearance of more severe symptoms such as intracranial hemorrhage or GI tract bleeding. In one study purpura was found in 32% of patients with APCD, even though purpura was not found even though bleeding at other sites persisted.

GI tract and intracranial hemorrhage are dangerous complications in infants born with coagulation disorders. The mortality in both cases is quite high, even if the patient survives, he or she will experience an accompanying disability for the rest of his life (Pitriyani, Noch, & AK, 2019) (Wahab, 2020). Somnolence appearance of the patient shows that the problems that occur are not only local, but there have been problems in the intracranial that cause decreased consciousness. In addition, the apneic period can be a seizure process that is often overlooked (Bruck, 1992). So an intracranial examination needs to be done. Due to the condition of the fontanelle that has not closed, an ultrasound examination can be carried out through the gap and it is found that there is intracerebral hemorrhage.

The results of the hematological examination showed a decrease in the level of platelets which is also one of the components of blood hemostasis. In several previous studies, APCD was not associated with a decrease in platelets, so the findings in this case were unique (Sipayung, Pakpahan, Widiyani, & Devi, 2019). One of the possible processes that cause a decrease in platelets in our patient is the possibility of consumptive coagulopathy that occurs in the intracranial as a form of compensation for the bleeding that occurs. In locations that occurs bleeding, many platelets recruited to carry out hemostasis which causes platelets in the peripheral veins to decrease (Krismen, 2014).

In our case we had a normal PT result and a prolonged aPTT. Although in many studies related to APCD, PT and aPTT are found to be prolonged, but it is necessary to carry out a more in-depth evaluation of what factors are experiencing the disorder. Because only looking at PT and aPTT alone could not assess the abnormality of the coagulation factors that occur in the patient.

The therapy given focuses on providing life-support to the patient. Giving mechanical ventilation to help the patient when there is apnea phase. Giving phenytoin and midazolam aims to prevent seizures in which the manifestations of seizures that occur are apneic seizures. Giving PRC transfusion is a support to overcome on-going bleeding that occurs in patients. New definitive therapy will be given when the patient's condition has stabilized.

CONCLUSION

Based on the analysis and discussion, it can be concluded that APCD is a disease with a high mortality rate, and those who survive are also threatened with disability for the rest of their lives. So that early detection and holistic treatment need to be done to prevent death and disability.

REFERENCES

- Bhanchet-Israngkura, P., & Kashemsant, C. (1975). A Bleeding Syndrome In Infants: Acquired Prothrombin Complex Deficiency Of Unknown Aetiology. *The Southeast Asian Journal Of Tropical Medicine And Public Health*, 6(4), 592–598.
- Bhanchet, P., Tuchinda, S., Hathirat, P., Visudhiphan, P., Bhamaraphavati, N., & Bukkavesa, S. (1977). A Bleeding Syndrome In Infants Due To Acquired Prothrombin Complex Deficiency: A Survey Of 93 Affected Infants. *Clinical Pediatrics*, 16(11), 992–998.
- Bruck, Maggie. (1992). Persistence Of Dyslexics' Phonological Awareness Deficits. *Developmental Psychology*, 28(5), 874–886. <https://doi.org/10.1037/0012-1649.28.5.874>
- Fristadi, Restu, & Bharata, Haninda. (2015). Meningkatkan Kemampuan Berpikir Kritis Siswa Dengan Problem Based Learning. *Seminar Nasional Matematika Dan Pendidikan Uny*, 597–602.
- Gretz, Richard T., & Basuroy, Suman. (2013). Why Quality May Not Always Win: The Impact Of Product Generation Life Cycles On Quality And Network Effects In High-Tech Markets. *Journal Of Retailing*, 89(3), 281–300.
- Gunawan, Alfa Adi, & Yoestini, Yoestini. (2011). *Pengaruh Produk, Harga, Distribusi Dan Promosi Terhadap Keputusan Pembelian Obat Batuk Vicks Formula 44 Di Swalayan Ada Di Semarang (Studi Pada Swalayan Ada Siliwangi)*. Universitas Diponegoro.
- Koojaroenprasit, Sauwaluck. (2012). The Impact Of Foreign Direct Investment On Economic Growth: A Case Study Of South Korea. *International Journal Of Business And Social Science*, 3(21).
- Krismen, Yudi. (2014). Pertanggungjawaban Pidana Korporasi Dalam Kejahatan Ekonomi. *Jurnal Ilmu Hukum*, 5(1), 61–70.
- Pantiyasa, I. Wayan. (2011). Pengembangan Pariwisata Berbasis Masyarakat (Community Based Tourism) Dalam Pemberdayaan Masyarakat (Studi Kasus Di Desa Bedulu, Blah Batuh, Gianyar). *Jurnal Ilmiah Hospitality Management*, 1(2).
- Pitriyani, Rita, Noch, R. Muchamad, & Ak, M. (2019). *Pengaruh Kompetensi Dan Integritas Terhadap Kualitas Audit (Survey Pada 9 Kantor Akuntan Publik Di Kota Bandung)*. Perpustakaan Feb Unpas.
- Scholes, Robert. (1998). The Case Against Phonemic Awareness. *Journal Of Research In Reading*, 21(3), 177–188. <https://doi.org/10.1111/1467-9817.00054>
- Sipayung, Erlita, Pakpahan, Kartina, Widiyani, Heni, & Devi, Nelly Sri. (2019). Perlindungan Hukum Terhadap Pihak Ketiga Sebagai Pemilik Alat Berat Yang Digunakan Dalam Melakukan Tindak Pidana Perambahan Hutan. *Jurnal Selat*, 6(2), 172–183.
- Unghusak, Kumnuan, Tishyadhigama, Surachai, Choprapawon, Chanpen, Sawadiwutiping, Witaya, & Varintarawat, Sirisak. (1988). Incidence Of Idiopathic Vitamin K Deficiency In Infants: A National, Hospital Based,

Farahdina Farahdina, Ima Sri Wahyuni, Vatine Adila

Survey In Thailand, 1983. *Chot Mai Het Thang Phaet*, 71(8), 417–421.

[Wahab, Abdul.](#) (2020). *Kemampuan Konsorsium Bakteri Sedimen Rawa Dalam Menurunkan Kandungan Sulfat Dan Kandungan Logam Berat Timbal (Pb) Pada Air Asam Tambang Batubara*. Makassar: Universitas Hasanuddin.