

COLLABORATION BETWEEN FORENSIC ODONTOLOGY AND FORENSIC PATHOLOGY IS CRUCIAL IN DISASTER VICTIM IDENTIFICATION

Muhammad Salman Khan¹, Antonius Winoto Suhartono², Elza Ibrahim Auerkari³

^{1,2,3} Division of Forensic Odontology, Department of Oral Biology, Faculty of Dentistry, Universitas Indonesia, Indonesia

Email: eauerkari@yahoo.com

ABSTRACT

While forensic pathologists have always played a pivotal role in victim identification after mass casualties, new developments in forensic methods have given forensic anthropologists more agency in positively identifying individuals who were previously unidentifiable. This review aims to contribute to the refinement of diagnostic tools, ensure optimal utilization of remnants and information available, and emphasize the contributions of forensic pathologists and forensic odontologist to victim identification and the importance of forensic pathologists and forensic odontologist in the criminal justice system. Considering the Interpol DVI Guide's emphasis on fingerprints, dental examinations, and DNA as primary identifiers, the forensic pathologist's role as the leader of a multidisciplinary team of experts in a disaster situation has taken on new significance. This is due to the forensic pathologist's and forensic odontologist training and experience leading similar teams during routine operations at a forensics institute. This thorough examination highlights the utmost significance of the job carried out by forensic pathologists and forensic odontologist. They play an important role in the judicial process by providing expert views in criminal investigations. Their expertise ensures accurate identification of victims and provides critical evidence that is necessary for holding offenders responsible. Their contributions are fundamental to the administration of justice, highlighting the great importance of their function in the overall structure of the criminal judicial system.

KEYWORDS Forensic Pathology, Disaster Victim Identification, Forensic Odontology



This work is licensed under a Creative Commons Attribution-ShareAlike 4.0 International

How to cite:

E-ISSN:

Published by:

Salman Khan, M et al. (2024). Collaboration between forensic odontology and forensic pathology is crucial in Disaster Victim Identification. *Journal Eduvest*. 4 (7): 6062-6074

2775-3727

<https://greenpublisher.id/>

INTRODUCTION

The field of forensic sciences, which is directly linked to the legal system, has a fundamental basis in humanistic principles. The significance of identification becomes of utmost importance in instances of serious bodily harm resulting from diverse situations, underscoring the crucial role played by forensic medicine and related fields in such circumstances (Cordner, 2018). Forensic anthropology, fingerprint analysis, forensic odontology (FO), radiography, and DNA profiling are many methodologies that may be used in such circumstances with the aim of facilitating victim identification. (Rodríguez Almada et al., 2022) The outstanding accuracy of dental identification as a key tool for determining the identity of a dead person is highlighted by the preservation of teeth and dental traits postmortem (PM). This method, which makes use of the tenacity of dental structures to continue after a person's death, stands out as one of the most dependable and accurate processes now accessible in the field of forensic research. (Prajapati et al., 2018a)

Forensic pathology examines dead bodies to determine cause, method, and circumstances. A forensic pathologist is a medically trained professional who has obtained a license to practice medicine. They have successfully finished a 4-year medical school program, followed by a 3-4 year residency in anatomic and clinical pathology, and finally, a year-long fellowship in forensic pathology. Upon successfully completing the anatomic pathology board test, forensic pathologists are eligible to undertake the forensic pathology exam administered by the American Board of Pathology. Unfortunately, the US lacks board-certified forensic pathologists; hence, many forensic examinations are performed by non-boarder pathologists with varied backgrounds. (Senn. David R, 2021)

Disaster victim identification

The teeth and dental features can be preserved postmortem (PM), dental identification is one of the most accurate procedures for determining the identity of a deceased individual (Shanbhag, 2016). During the process of identification, recovery, antemortem, postmortem, and identification, teams will all be involved.

Recovery team for disaster victims

Dental identification, given the resilience of teeth and dental features postmortem, emerges as a highly accurate forensic procedure, playing a pivotal role in determining the identity of deceased individuals. This is necessary in order to prevent the degradation of dental substances while the body is being transported to the morgue. (de Boer et al., 2020)

Ante Mortem team

The first responsibility of the AM team is to gather compilations of individuals who are currently unaccounted for. The information is obtained from the family and physician of the missing individual. Following the local police's communication with the missing person's dentist, a forensic odontologist is assigned to the AM team to disseminate the dental AM, data, and materials. Gathering and documenting

information from various sources such as dental records, X-rays, CT scans, dental models, and full-face photos, and entering it into the AM F1/F2 Interpol form. A centralized computer system, such as DVI System International, WinID, DAVID, or another application, is used to keep the personal, medical, and dental data obtained from the experts. In addition, the AM fingerprints that have been recorded are received and scanned into the AFIS. (Smitha et al., 2019a)

Post-mortem team

Fingerprint experts, police officers, pathologists, odontologists, and DNA experts are just some of the professionals who will examine the corpse at the morgue and record their findings on post mortem Interpol form. The PM examination begins with a detailed exterior description and then moves on to fingerprint analysis. The following phase involves the pathologist beginning an exterior and interior body description. Subsequently, a forensic odontologist would examine the teeth on the postmortem f1/f2, , We will maintain a comprehensive record of the patient's dental condition, including details about their teeth, surrounding structures, fillings, materials used, and any prosthetic procedures performed. The pulp from two primary teeth (canines and premolars) can be extracted and sent to forensic DNA labs for investigation (Smitha et al., 2019b).

Identification team

Documents pertaining to missing people are processed and compared at the identification center, which also transcribes and reconciles fingerprint, dental, and DNA analysis results sent over from the AM and PM files units. Feedback from the specialist area is used to update the corresponding identifying records. According to the DVI Guide: Interpol 2009, the most reliable methods of individual identification include fingerprint analysis, comparative dental examination, and DNA analysis. It is also suggested that positive identification may be achieved using a combination of postmortem and antemortem dental evidence obtained from the same person. According to the Interpol DVI Guide, a single positive match achieved via the use of dental identification may be relied upon as a reliable identify (Smitha et al., 2019c).

RESEARCH METHOD

Dental identification

Disasters, both natural and human-caused, have always highlighted the need for dental identification. Because there isn't enough space for fingerprints in any central database, dental identification remains essential (Kaleelullah & Hamid, 2020).

Identification reports, as defined by the American Board of FO,

1. Accurately matching data records provides a positive identification.
2. AM and PM recordings with comparable traits but questionable evidence for identification
3. Evidence is insufficient because there is not enough of it to draw a conclusion.

Not matching records are excluded.

There are two methods of dental identification:

Collaboration between forensic odontology and forensic pathology is crucial in Disaster Victim Identification

1. The dentist will check for comparable or confirming dental traits in the dead individual from the suspect's past dental records.
2. If there are no known dental records that may help identify a body using AM materials, a dental profile can be created using PM method (21: *Forensic Odontology | Pocket Dentistry*, n.d.)

Dental Record

It is a formal record of the patient's history, including both personal and clinical details. Accurate notation is required on the dental chart. (Pretty et al., n.d.). It includes the status of each tooth in the mouth, including whether it is there, whether it has been restored, whether or not it has been affected by any diseases or conditions, and so on. Dentists are required by law to keep dental records that are both complete and legible (Roy et al., 2019).

Definitive identification of deceased individuals may be accomplished by comparing ante-mortem (AM) records, such as a comprehensive medical history sheet with dental information, written notes, study casts, full mouth impressions, dental radiographs, and high-resolution photographs, with post-mortem (PM) findings. Dental records maintained by AM dentists are very helpful for major crises. (Astekar et al., n.d.)

The steps used to gather dental history should be in line with state regulations. Any departure from the proper legal procedures for disclosing the documents might have serious consequences (Li et al., 2022). The "Disaster Victim Register" method must be implemented in the event of a major catastrophe. For purposes of comparison, please fill out the yellow AM form and the pink PM form independently (Dahal et al., 2022). To assist in the identification of the victim roster in digital format, Plass Data (Plass Data Software A/S, Taastrup Moellevej 12A, 4300 Holbaek, Denmark) developed the "DVI System International" program (Kaur Ekampreet et al., 2022).

Post-mortem dental profiling

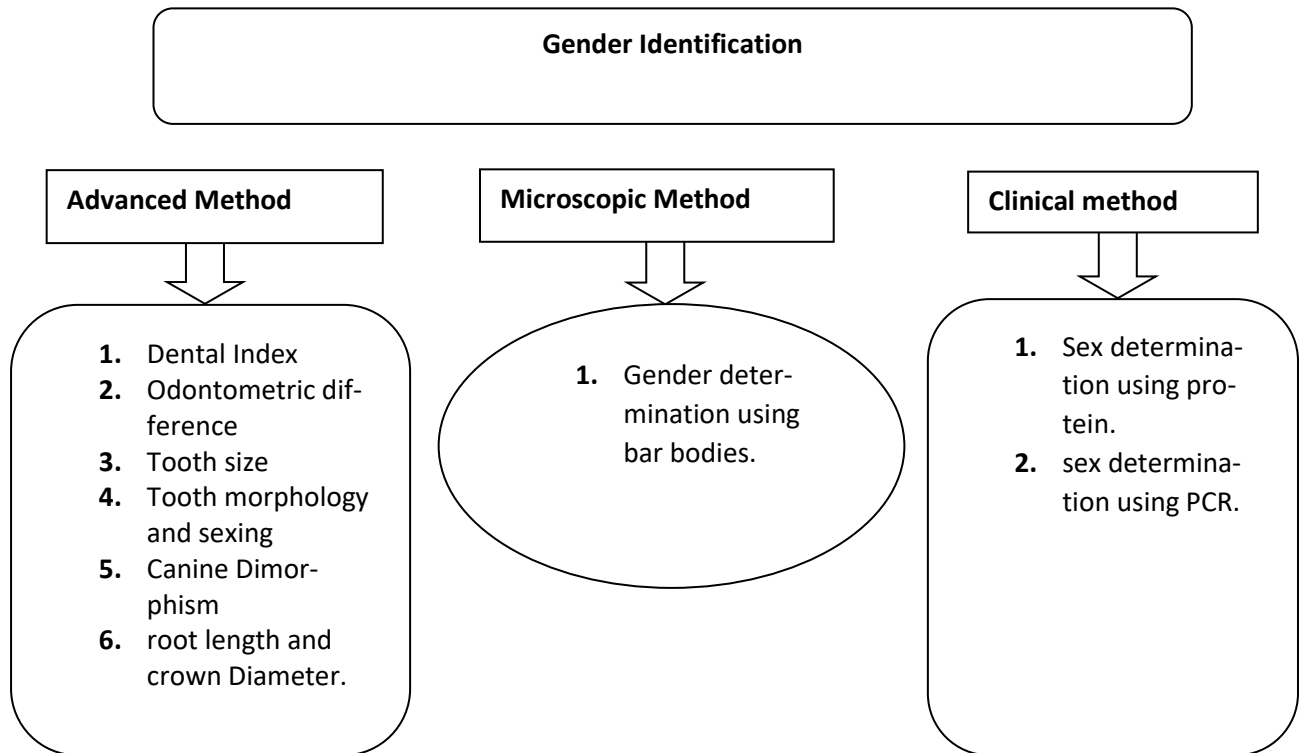
When the suspect's presumed identification is unknown and no AM records are accessible, dental anthropology (M dental profiling) is used. When the bones are badly decomposed and discovered in a random place, this kind of scenario might emerge. (Pramod et al., n.d.) The goal of PM dental profiling is to identify a select group of candidates for further investigation. The dental profile is an individual's unique set of hard and soft tissue traits. Age, sex, race, socioeconomic position, personal habits, systemic health, employment, and nutrition may all be estimated with their guidance. (Vodanović et al., n.d.)

Sex determination

Human identification by a forensics team begins with establishing sex. A forensic odontologist uses teeth and skeletal evidence to help with gender identification (Nagare et al., 2018a). Males and females differ in several ways, including tooth shape, crown size, and root length. Teeth are resistant to PM degradation, making them a useful tool in gender identification. Multiple approaches were employed to identify individuals based on their gender (DAVID

THOMAS J & LEWIS JAMES M, 2018).

[Table 1]. sex determination method



Teeth size is a reliable indicator of sexual orientation. The linear dimensions of teeth have been used to create indices such as the incisor index, the mandibular canine index (MCI), and the crown index. These indices reveal sexual dimorphism in teeth.(Sabóia et al., n.d.)The crown sizes of male and female teeth have been shown to be statistically different. Larger teeth in the mandibular canine region are more often seen in men than women (Shah et al., 2019). The incisors, premolars, first molars, and second molars all have their own unique characteristics (Monali et al., n.d.) The diameter of the plant's crown and various root lengths are also utilized to establish its gender. In their research, Singh et al. discovered that men had larger intercanine distances, right canine widths, left canine widths, molar contact indices (MCIs), and MCIs.

Nonmetric characteristics that may be used to determine sex include the presence or absence of a distal accessory ridge, the presence of Carrabelle’s trait in the upper molars, the shoveling of the upper central incisor, and the number of cusps in the mandibular first molar. Males of the canine species have a more prominent distal accessory ridge compared to females. The female mandibular first molar has a reduced number of distobuccal or distal cusps compared to its male counterpart. Research has shown that men have a greater prevalence of the crown and Carrabelle's tubercle in terms of their size. A recent study has shown that the detection of bar bodies in the tooth pulp may serve as a dependable method for

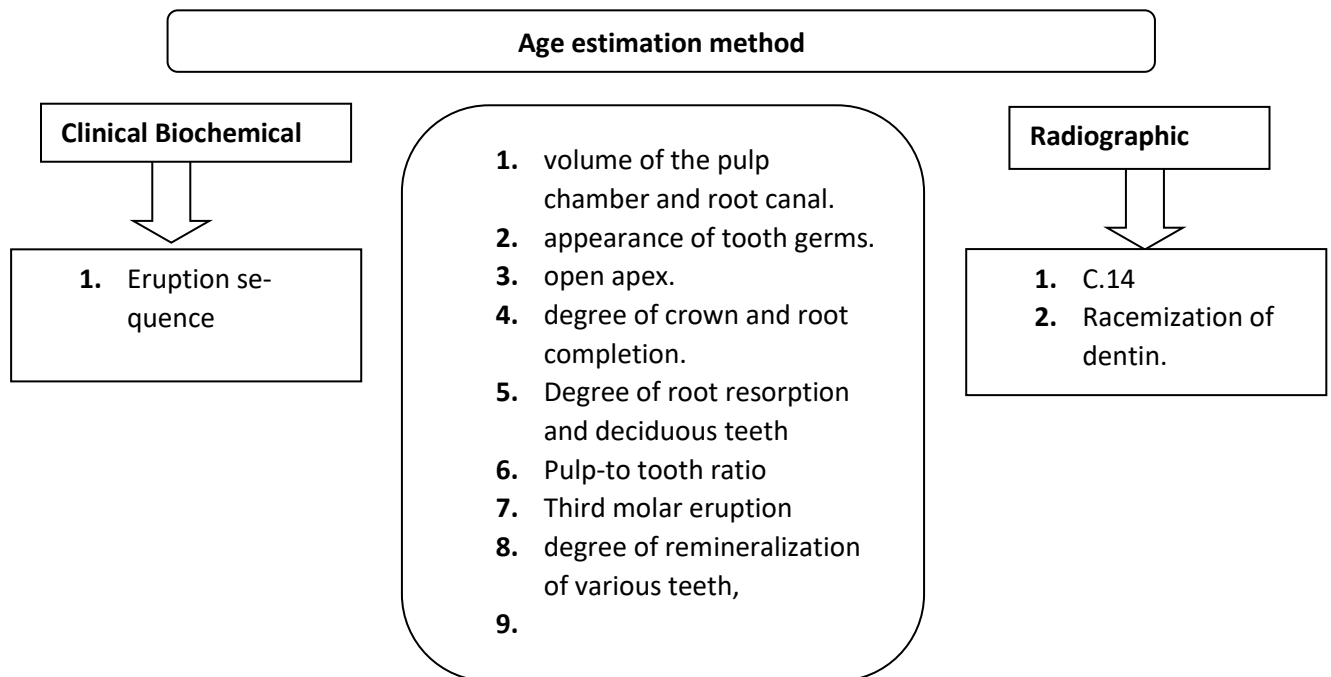
Collaboration between forensic odontology and forensic pathology is crucial in Disaster Victim Identification

determining an individual's sex (Nagare et al., 2018b). At temperatures of 100°C, 200°C, and 400°C, the female cells in the study by Reddy et al. demonstrated peripheral Barr chromatin condensation. On the other hand, the male cells did not display Barr chromatin but did exhibit a fibrovascular connective tissue stroma. (Sivagami et al., n.d.-a) Polymerase chain reaction (PCR) is used to determine sex using DNA extracted from pulp tissue (Reddy et al., n.d.). Using ultrasonication and PCR amplification, Sivagami et al. were able to successfully determine the sex of 2000 individuals (Sivagami et al., n.d.-b). The human enamel protein AMELOGENIN, or AMEL, has a sex-specific distribution. In men, AMEL genes are found on both X and Y chromosomes, whereas females have two copies of ALEL on the X chromosome (Ginart et al., 2019).

Age estimation

Dental age may be used for identification purposes since it remains unchanged by an individual's nutritional or endocrine condition (Puranik et al., 2015). Several techniques are included in the age estimate process of human identification, as shown in Table 2.

Table 2. Age estimation method



Dentition is used as a reliable indicator of age throughout the stages of prenatal, natal, and postnatal development, as well as in individuals ranging from newborns to adolescents and adults. Age estimation during the new-born period is conducted for objectives such as infanticide. Neonatal ages may be approximated using many techniques, including as maceration, CT scans, dry tooth weight, and the neonatal line. Radiographic techniques, including Schouler and Mossler's

method, the Moorer, Fanning, and Hunt method, the Demirjian, Goldstein, and Taner's method, and Nola's methodology, are used to assess the age of children and young adults. These methods are complemented by clinical procedures such as the eruption sequence (De Donno et al., 2021).

The eruption of the third molar is a crucial indicator of adulthood. Age estimation may be facilitated by observing regressive alterations in adult teeth, the periodontal condition including attachment loss, histological changes in dentin such as incremental lines of cementum, and radiographic assessment of root resorption and cementum apposition at the apex (Singhal et al., n.d.). Factors such as occlusal attrition, coronary secondary development, loss of periodontal attachment, cementum apposition, apical resorption, and root transparency are taken into consideration in Gustafson's approach for calculating age from a single (DIAC et al., 2020) created a technique for determining an adult's age. The age is determined by comparing the pulp volume to the tooth volume.

According to Harris and Nortje, the root production of the third molar goes through five phases (Verma et al., 2019). This has potential use in determining an individual's age (da Silva Sampieri et al., 2018). New studies suggest that the angulation of the cementum of a tooth may be used as a more accurate proxy for age than previous approaches (Pinto et al., 2022). Age may also be calculated by measuring amino acid racemization. Enamel, dentine, and cementum convert more L-aspartic acid to D-aspartic acid with age; hence, this ratio may be used to determine a person's age (Adserias-Garriga et al., 2018).

RESULT AND DISCUSSION

Race determination

Several dental anthropological investigations have demonstrated that tooth shape and size may be used as indicators of racial identity. The Carabelli cusp, fewer dental cusps overall, and a streamlined fissure system are all traits often associated with Caucasians. In contrast to the Western trend of reducing the number of dental cusps, Asians have a disproportionately high incidence of shovelled incisors and a complicated fissure system. African-descended persons do not often have the Carrabelli cusp or shovelled incisors, but they do have a complex fissures and number of cusps (Hillson Simon, 2024).

An individual's distinct amalgamation of socioeconomic status, personal behaviors, oral health, and occupation might be used to definitively establish their identity. The person may exhibit inappropriate behavior, such as smoking, using oral hygiene products, having an open bite crossbite, or protrusive incisors. Identity may be determined by analyzing PM dental data, including conditions such as amelogenesis imperfecta, dentinogenesis imperfecta, oral signs of scurvy, and erosive changes caused by bulimia or anorexia. Consumption of carbohydrates, tough foods, nuts, and carbonated beverages may be associated with an elevated caries index, tooth abrasion, and erosive changes in hard dental tissue (Kapoor & Chowdhry, 2018).

Role of forensic odontologist

Forensic Odontologist

When determining where an unknown body belongs, the forensic odontologist is essential. (Pittayapat et al., n.d.). Forensic science and the legal system generally agree that teeth may be used for positive identification purposes.(Krishan et al., n.d.) In the following paragraphs, we'll discuss why a forensic odontologist's expertise and a team-based approach are crucial to a successful forensic investigation.

Mass disaster

Since the beginning of this century, the number of catastrophic events that affect many people has skyrocketed, mostly as a result of two factors: the proliferation of transportation options and a rise in the frequency of extreme weather.(Prajapati et al., 2018b) In this case, a forensic odontologist is the only one who can positively identify a victim.

Identification of useless cadavers

It is possible for forensic odontologists to give families with proof that may be utilized in court as a result of the identification of nameless cadavers. This also ensures that the corpse can be made accessible to the family in time for the burial. It is also helpful to understand what occurred to the person who passed away, so that the corrosive confusion over this may be replaced with something that is closer to the reality, even though this may be quite upsetting.(Cordner et al., n.d.)

The purpose is to emphasize that forensic pathologists are not only responsible for determining the cause and manner of death but also play a critical role in aiding investigations, bringing closure to families and loved ones of the victims, and ensuring justice is served. Ultimately, the purpose of this discussion is to highlight the significance of forensic pathologists in the criminal justice system and recognize their contributions to victim identification.

CONCLUSION

It has been shown that an effective technique for enhancing the field of forensic science is to include forensic dentistry and forensic pathology into the field. The information that is obtained via these methods may be used to provide crucial insights into criminal investigations and to aid in the process of delivering justice to victims and the families of those who have been mistreated. Identification of victims of disasters is a difficult and time-consuming task that requires the use of multidisciplinary teams that have been properly prepared and are handled. The pathologist is responsible for collecting the relevant samples for DNA analysis, reviewing the X-rays or CT scans, and, if necessary, consulting with radiology professionals who are skilled with the interpretation of postmortem imaging. In order to perform this duty to the best of their ability, the pathologist must have proper training and education in disaster management.

REFERENCES

- 21: *Forensic Odontology / Pocket Dentistry*. (n.d.). Retrieved January 3, 2024, from <https://pocketdentistry.com/21-forensic-odontology/>
- Adserias-Garriga, J., Thomas, C., Ubelaker, D. H., & C. Zapico, S. (2018). When forensic odontology met biochemistry: Multidisciplinary approach in forensic human identification. *Archives of Oral Biology*, 87, 7–14. <https://doi.org/10.1016/J.ARCHORALBIO.2017.12.001>
- Astekar, M., Saawarn, S., ... G. R.-J. of forensic, & 2011, undefined. (n.d.). Maintaining dental records: Are we ready for forensic needs? *Ncbi.Nlm.Nih.GovM Astekar, S Saawarn, G Ramesh, N SaawarnJournal of Forensic Dental Sciences, 2011•ncbi.Nlm.Nih.Gov*. Retrieved November 12, 2023, from <https://www.ncbi.nlm.nih.gov/pmc/articles/PMC3296374/>
- Cordner, S. (2018). Humanitarian forensic science. *Australian Journal of Forensic Sciences*, 50(6), 639–650. <https://doi.org/10.1080/00450618.2018.1461930>
- Cordner, S., International, M. T.-B.-F. S., & 2017, undefined. (n.d.). Humanitarian forensic action—its origins and future. *Elsevier*. Retrieved November 12, 2023, from <https://www.sciencedirect.com/science/article/pii/S0379073817303109>
- da Silva Sampieri, M. B., Viana, F. L. P., Cardoso, C. L., Vasconcelos, M. F., Vasconcelos, M. H. F., & Gonçalves, E. S. (2018). Radiographic study of mandibular third molars: evaluation of the position and root anatomy in Brazilian population. *Oral and Maxillofacial Surgery*, 22(2), 163–168. <https://doi.org/10.1007/S10006-018-0685-Y/FIGURES/2>
- Dahal, S., Chaudhary, G. K., Maharjan, M. R., & Walung, E. D. (2022). A Dental Perspective on the Successes and Limitations of the Disaster Victim Identification Response to the Nepal Earthquake. *Forensic Sciences Research*, 7(3), 366–370. <https://doi.org/10.1080/20961790.2022.2034716>
- DAVID THOMAS J, & LEWIS JAMES M. (2018). *Forensic Odontology: Principles and Practice - Thomas J. David, Jim Lewis - Google Books*. https://books.google.co.id/books?hl=en&lr=&id=JikzDwAAQBAJ&oi=fnd&pg=PP1&dq=Textbook+of+forensic+odontology.&ots=ncm-JRkQCe&sig=vDpjIdMd4Muh7YMwKiVUAur-snY&redir_esc=y#v=onepage&q=Textbook%20of%20forensic%20odontology.&f=false
- de Boer, H. H., Roberts, J., Delabarde, T., Mundorff, A. Z., & Blau, S. (2020). Disaster victim identification operations with fragmented, burnt, or commingled remains: experience-based recommendations. *Forensic Sciences Research*, 5(3), 191–201. <https://doi.org/10.1080/20961790.2020.1751385>
- De Donno, A., Angrisani, C., Mele, F., Introna, F., & Santoro, V. (2021). Dental age estimation: Demirjian's versus the other methods in different populations. A literature review. <https://doi.org/10.1177/0025802420934253>, 61(1_suppl), 125–129. <https://doi.org/10.1177/0025802420934253>
- DIAC, Maria Mădălina, IOV, Tatiana, KNIELING, Anton, DAMIAN, Irina imona, TABIAN, Daniel, ILIESCU BULGARU, & Diana. (2020). *DENTAL IDENTIFICATION IN FORENSIC ANTHROPOLOGY. A LITERATURE REVIEW. | International Journal of Medical Dentistry | EBSCOhost*. 24(3), 464.

- <https://openurl.ebsco.com/EPDB%3Agcd%3A2%3A7947730/detailv2?sid=ebsco%3Aplink%3Ascholar&id=ebsco%3Agcd%3A146571012&crl=c>
- Ginart, S., Caputo, M., Corach, D., & Sala, A. (2019). Human DNA degradation assessment and male DNA detection by quantitative-PCR followed by high-resolution melting analysis. *Forensic Science International*, 295, 1–7. <https://doi.org/10.1016/J.FORSCIINT.2018.11.013>
- Hillson Simon. (2024). *Dental Anthropology - Simon Hillson - Google Books* (SECOND). https://books.google.co.id/books?hl=en&lr=&id=HEPGEAAAQBAJ&oi=fnd&pg=PR15&dq=Anthropology+of+modern+human+teeth.&ots=ZTxKYWLnzz&sig=0Lec8Ba5YDP5YcXI73C7VLaxWQI&redir_esc=y#v=onepage&q=Anthropology%20of%20modern%20human%20teeth.&f=false
- Kaleelullah, R. A., & Hamid, P. (2020). *Forensic Odontology, a Boon and a Humanitarian Tool: A Literature Review*. <https://doi.org/10.7759/cureus.7400>
- Kapoor, P., & Chowdhry, A. (2018). Salivary signature in forensic profiling: A scoping review. *Journal of Forensic Dental Sciences*, 10(3), 123. https://doi.org/10.4103/JFO.JFDS_30_18
- Kaur Ekampreet, Singh Jaskaran, Belhaj Meriem, Chadly Ali, & Awasthi Supriya. (2022). Investigation of Disaster Victim Identification | SpringerLink. *Crime Scene Management within Forensic Science*, 185–210. https://link.springer.com/chapter/10.1007/978-981-16-6683-4_8
- Krishan, K., Kanchan, T., journal, A. G.-T. open dentistry, & 2015, undefined. (n.d.). Dental evidence in forensic identification—An overview, methodology and present status. *Ncbi.Nlm.Nih.GovK Krishan, T Kanchan, AK GargThe Open Dentistry Journal, 2015•ncbi.Nlm.Nih.Gov*. Retrieved November 12, 2023, from <https://www.ncbi.nlm.nih.gov/pmc/articles/PMC4541412/>
- Li, S., Rajapuri, A. S., Felix Gomez, G. G., Schleyer, T., Mendonca, E. A., & Thyvalikakath, T. P. (2022). How Do Dental Clinicians Obtain Up-To-Date Patient Medical Histories? Modeling Strengths, Drawbacks, and Proposals for Improvements. *Frontiers in Digital Health*, 4. <https://doi.org/10.3389/FDGTH.2022.847080>
- Medicine, V. S.-S. R. J. of, & 2014, undefined. (n.d.). FORENSIC ODONTOLOGY: A BRIEF REVIEW. *Search.Ebscohost.ComV SaranyaSri Ramachandra Journal of Medicine, 2014•search.Ebscohost.Com*. Retrieved November 12, 2023, from https://search.ebscohost.com/login.aspx?direct=true&profile=ehost&scope=site&authtype=crawler&jrnl=09739939&asa=Y&AN=113728445&h=Rjz5517jsJPJXY0QcQ7W%2BPmEPVpfaD3Clqean2dgNtOiMYcFiZJeu2NXBHWhug%2FUGt5vSv7LzRHpQ7NXkPJ%2Fg%3D%3D&crl=c&casa_token=5Njx9uFiWpAAAAAA:N13OkZtBOHlr5BuwBy69dKM0Vo83_6ojFxbg9R Pm2cU_PvS_8zX9DkwH5HLY68vNfy2XIU63BMU0zO5Z
- Monali, C., Pritam, P., Tapan, M., Pathol, D. K.-I. J. F. M., & 2011, undefined. (n.d.). Gender determination: A view of forensic odontologist. *Oroscan.ComC Monali, P Pritam, M Tapan, D KajalIndian J Forensic Med Pathol, 2011•oroscans.Com, 4(4)*. Retrieved November 12, 2023, from <https://oroscans.com/pdf/1.pdf>

- Nagare, S. P., Chaudhari, R. S., Birangane, R. S., & Parkarwar, P. C. (2018a). Sex determination in forensic identification, a review. *Journal of Forensic Dental Sciences*, *10*(2), 61. https://doi.org/10.4103/JFO.JFDS_55_17
- Nagare, S. P., Chaudhari, R. S., Birangane, R. S., & Parkarwar, P. C. (2018b). Sex determination in forensic identification, a review. *Journal of Forensic Dental Sciences*, *10*(2), 61. https://doi.org/10.4103/JFO.JFDS_55_17
- Pinto, P. H. V., Fares, L. C., & Silva, R. H. A. da. (2022). Dental age estimation by cementum incremental lines counting: A systematic review and meta-analysis. *Forensic Science International*, *341*, 111492. <https://doi.org/10.1016/J.FORSCIINT.2022.111492>
- Pittayapat, P., Jacobs, R., ... E. D. V.-T. J. of, & 2012, undefined. (n.d.). Forensic odontology in the disaster victim identification process. *Ncbi.Nlm.Nih.GovP Pittayapat, R Jacobs, E De Valck, D Vandermeulen, G WillemsThe Journal of Forensic Odonto-Stomatology, 2012*•*ncbi.Nlm.Nih.Gov*. Retrieved November 12, 2023, from <https://www.ncbi.nlm.nih.gov/pmc/articles/PMC5734849/>
- Prajapati, G., Sarode, S. C., Sarode, G. S., Shelke, P., Awan, K. H., & Patil, S. (2018a). Role of forensic odontology in the identification of victims of major mass disasters across the world: A systematic review. *PLOS ONE*, *13*(6), e0199791. <https://doi.org/10.1371/JOURNAL.PONE.0199791>
- Prajapati, G., Sarode, S. C., Sarode, G. S., Shelke, P., Awan, K. H., & Patil, S. (2018b). Role of forensic odontology in the identification of victims of major mass disasters across the world: A systematic review. *PLoS ONE*, *13*(6). <https://doi.org/10.1371/JOURNAL.PONE.0199791>
- Pramod, J., Marya, A., journal, V. S.-D. research, & 2012, undefined. (n.d.). Role of forensic odontologist in post mortem person identification. *Ncbi.Nlm.Nih.GovJB Pramod, A Marya, V SharmaDental Research Journal, 2012*•*ncbi.Nlm.Nih.Gov*. Retrieved November 12, 2023, from <https://www.ncbi.nlm.nih.gov/pmc/articles/PMC3612186/>
- Pretty, I., journal, D. S.-B. dental, & 2001, undefined. (n.d.). A look at forensic dentistry–Part 1: The role of teeth in the determination of human identity. *Nature.ComIA Pretty, D SweetBritish Dental Journal, 2001*•*nature.Com*. Retrieved November 12, 2023, from <https://www.nature.com/articles/4800972>
- Puranik, M., Uma, S. R., Priyadarshini, C., Puranik, M. P., & Uma, S. R. (2015). DENTAL AGE ESTIMATION METHODS-A REVIEW. In *International Journal of Advanced Health Sciences* •. https://www.researchgate.net/profile/Manjunath-Puranik/publication/291343131_Dental_Age_Estimation_Methods_A_Review/links/56a220e608ae24f627057eaf/Dental-Age-Estimation-Methods-A-Review.pdf
- Reddy, A., Prakash, A., ... L. K.-J. of F., & 2017, undefined. (n.d.). Gender determination using barr bodies from teeth exposed to high temperatures. *Ncbi.Nlm.Nih.GovAVS Reddy, AR Prakash, LK Killampalli, M Rajinikanth, G Sreenath, PB SabihaJournal of Forensic Dental Sciences, 2017*•*ncbi.Nlm.Nih.Gov*. Retrieved November 12, 2023, from <https://www.ncbi.nlm.nih.gov/pmc/articles/PMC5450486/>

- Rodríguez Almada, H., Borches Duhalde, F., & Iglesias Salaverría, V. (2022). Human rights and humanitarian forensic action: the experience in Uruguay. *Forensic Sciences Research*, 7(3), 378. <https://doi.org/10.1080/20961790.2022.2052591>
- Roy, J., Rohith, M. M., Nilendu, D., & Johnson, A. (2019). Qualitative assessment of the dental groove pattern and its uniqueness for forensic identification. *Journal of Forensic Dental Sciences*, 11(1), 42. https://doi.org/10.4103/JFO.JFDS_73_19
- Sabóia, T., Tannure, P., ... R. L.-D., & 2013, undefined. (n.d.). Sexual dimorphism involved in the mesiodistal and buccolingual dimensions of permanent teeth. *Dentistry3000.Pitt.EduTM Sabóia, PN Tannure, RR Luiz, M de Castro Costa, JM Granjeiro, EC KüchlerDentistry 3000, 2013•dentistry3000.Pitt.Edu*. Retrieved November 12, 2023, from <http://dentistry3000.pitt.edu/ojs/dentistry3000/article/view/10>
- Senn.David R, Weem. R. A. (2021). *MANUAL OF FORENSIC ODONTOLOGY*. (5th Education). CRC PRESS. <https://www.routledge.com/Manual-of-Forensic-Odontology/Senn-Weems/p/book/9780367778514>
- Shah, P., Velani, P., Lakade, L., & Dukle, S. (2019). Teeth in forensics: A review. *Indian Journal of Dental Research*, 30(2), 291–299. https://doi.org/10.4103/IJDR.IJDR_9_17
- Shanbhag, V. K. (2016). Significance of Dental Records in Personal Identification in Forensic Sciences. In *Journal of Forensic Science and Medicine* (Vol. 2, Issue 1, pp. 39–43). Wolters Kluwer Medknow Publications. <https://doi.org/10.4103/2349-5014.155551>
- Singhal, I., Arora, M., Dave, A., & Saluja, P. (n.d.). *Encompassing the Domains of Forensic Odontology as a reliable Tool in determining Age-a Brief Review*. Retrieved January 3, 2024, from <http://www.bepls.com>
- Sivagami, A., Rao, A., international, U. V.-F. science, & 2000, undefined. (n.d.-a). A simple and cost-effective method for preparing DNA from the hard tooth tissue, and its use in polymerase chain reaction amplification of amelogenin gene. *Elsevier*. Retrieved November 12, 2023, from <https://www.sciencedirect.com/science/article/pii/S0379073800001559>
- Sivagami, A., Rao, A., international, U. V.-F. science, & 2000, undefined. (n.d.-b). A simple and cost-effective method for preparing DNA from the hard tooth tissue, and its use in polymerase chain reaction amplification of amelogenin gene. *Elsevier*. Retrieved November 12, 2023, from <https://www.sciencedirect.com/science/article/pii/S0379073800001559>
- Smitha, T., Sheethal, H. S., Hema, K. N., & Franklin, R. (2019a). Forensic odontology as a humanitarian tool. *Journal of Oral and Maxillofacial Pathology: JOMFP*, 23(1), 164. https://doi.org/10.4103/JOMFP.JOMFP_249_18
- Smitha, T., Sheethal, H. S., Hema, K. N., & Franklin, R. (2019b). Forensic odontology as a humanitarian tool. *Journal of Oral and Maxillofacial Pathology: JOMFP*, 23(1), 164. https://doi.org/10.4103/JOMFP.JOMFP_249_18

- Smitha, T., Sheethal, H. S., Hema, K. N., & Franklin, R. (2019c). Forensic odontology as a humanitarian tool. *Journal of Oral and Maxillofacial Pathology: JOMFP*, 23(1), 164. https://doi.org/10.4103/JOMFP.JOMFP_249_18
- Verma, M., Verma, N., Sharma, R., & Sharma, A. (2019). Dental age estimation methods in adult dentitions: An overview. *Journal of Forensic Dental Sciences*, 11(2), 57. https://doi.org/10.4103/JFO.JFDS_64_19
- Vodanović, M., umjetnosti, H. B.-R. H. akademije znanosti i, & 2012, undefined. (n.d.). Dental profiling in forensic sciences. *Hrcak.Srce.HrM Vodanović, H BrkićRad Hrvatske Akademije Znanosti i Umjetnosti. Medicinske Znanosti, 2012•hrcak.Srce.Hr.* Retrieved November 12, 2023, from <https://hrcak.srce.hr/clanak/135009>